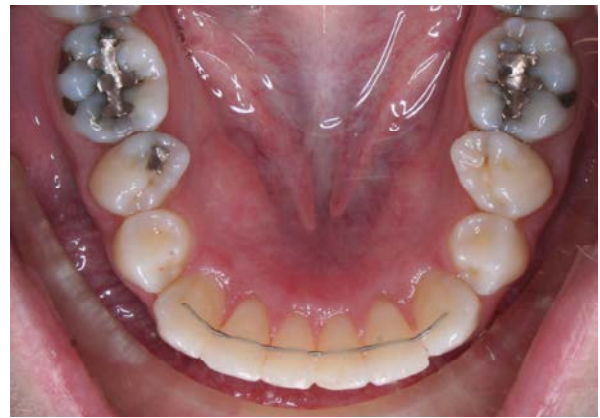
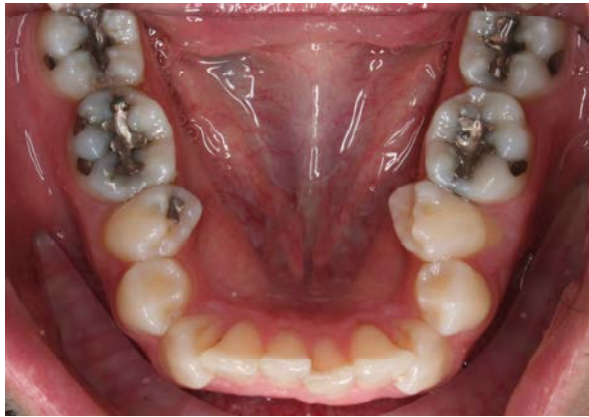
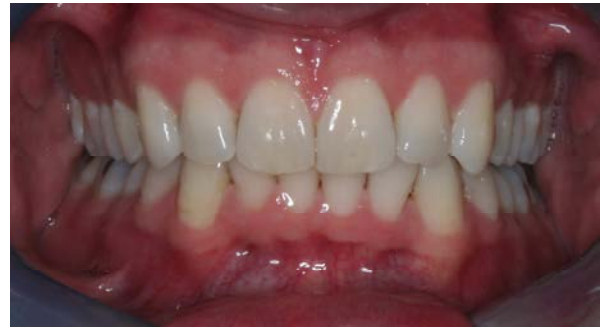
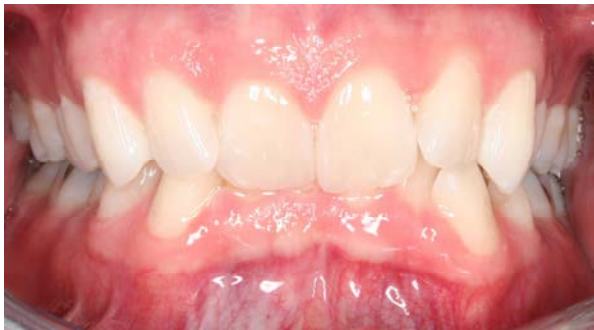
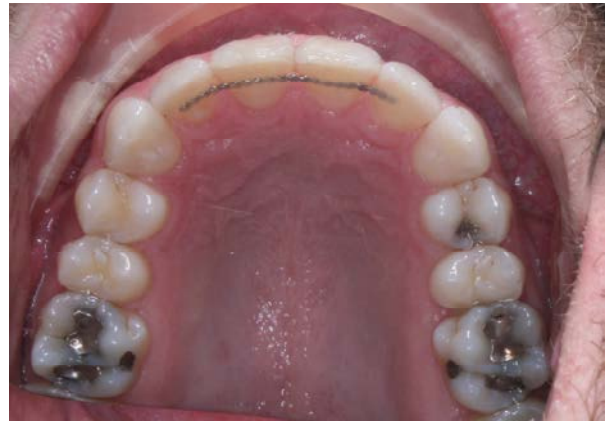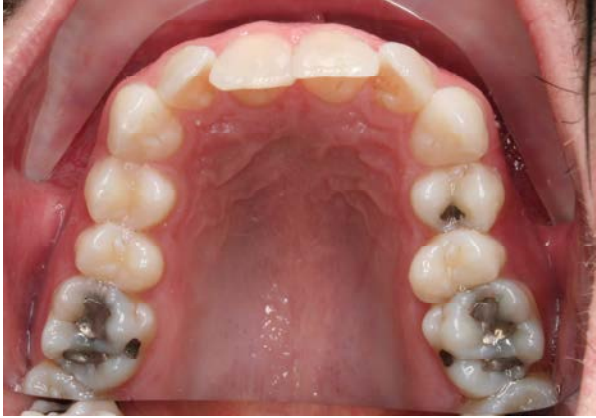Invisalign[®] Cases

Cases Treated by:
Bella Shen Garnett, DMD, MMSc



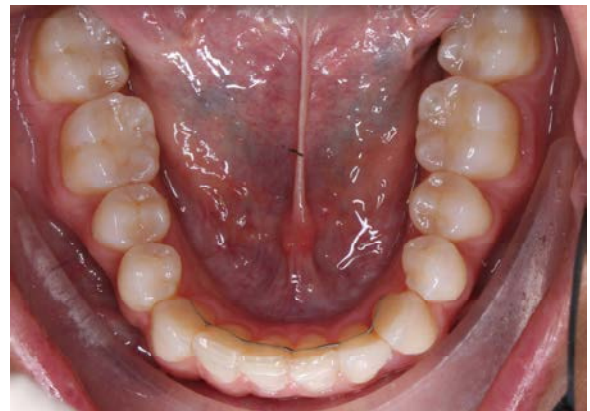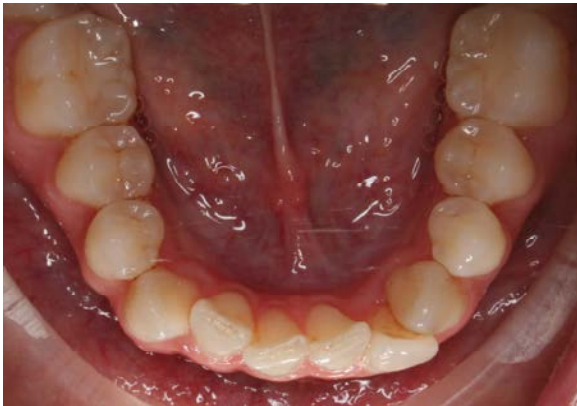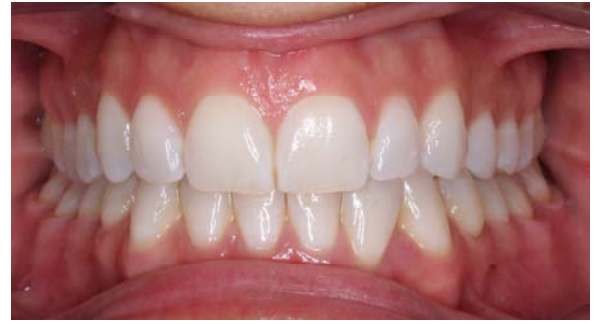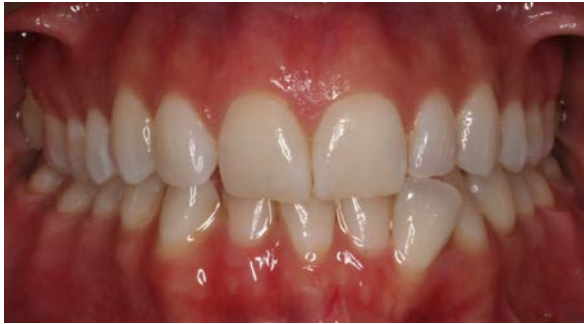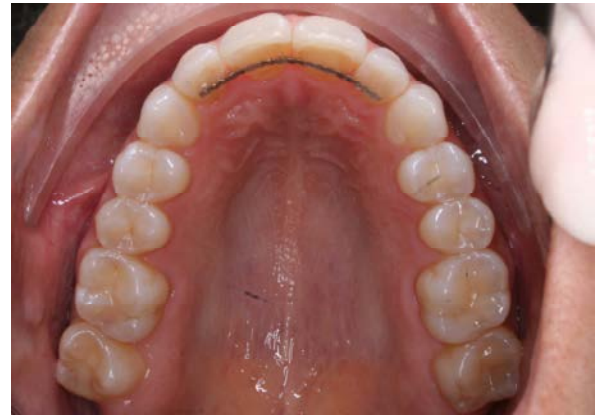
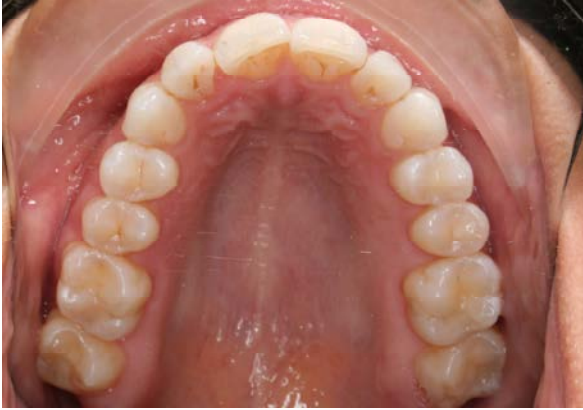Before

After

Constricted arch form and severe deep bite treated with Invisalign®
Treatment Length: 19 months



Treated by Dr. Bella Shen Garnett



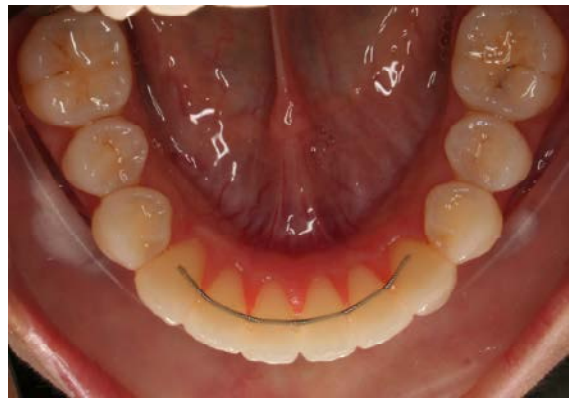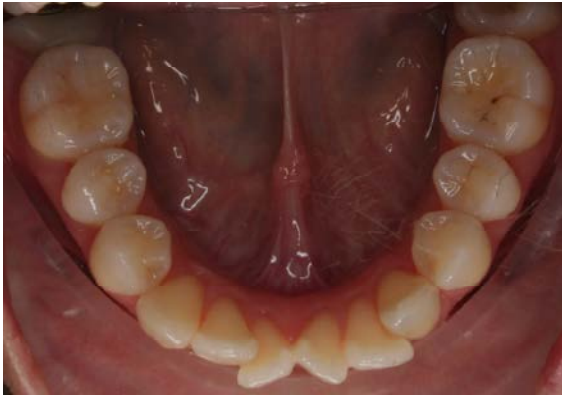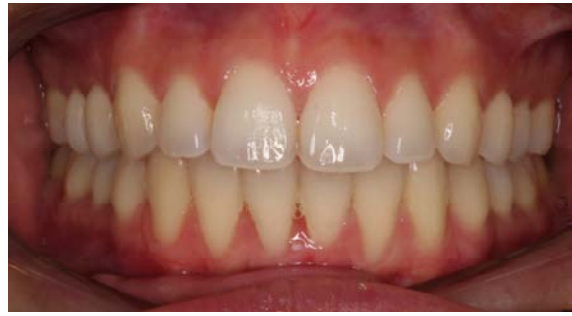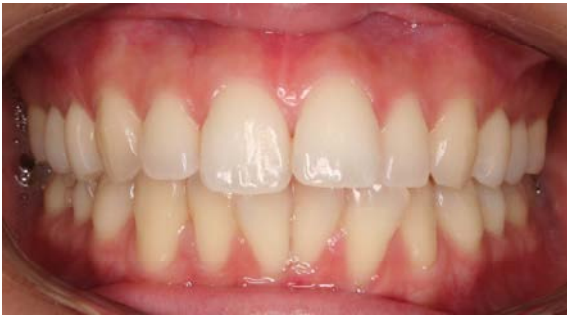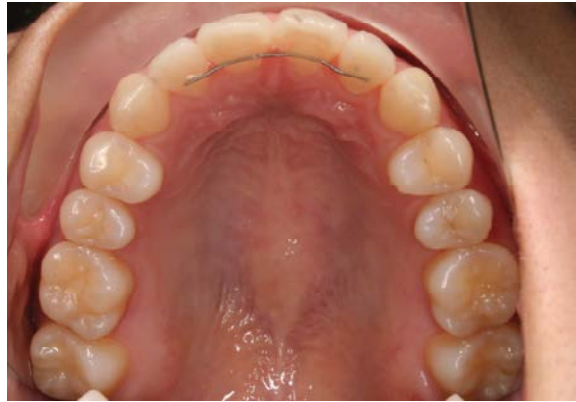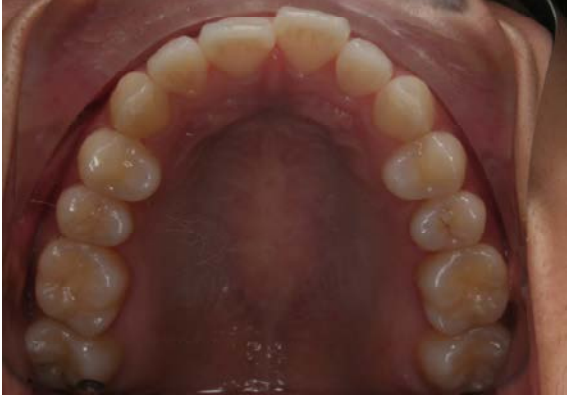Before

After

Uprighting Roots with Invisalign® and correcting the midline discrepancy
Treatment Length: 18 months



Treated by Dr. Bella Shen Garnett



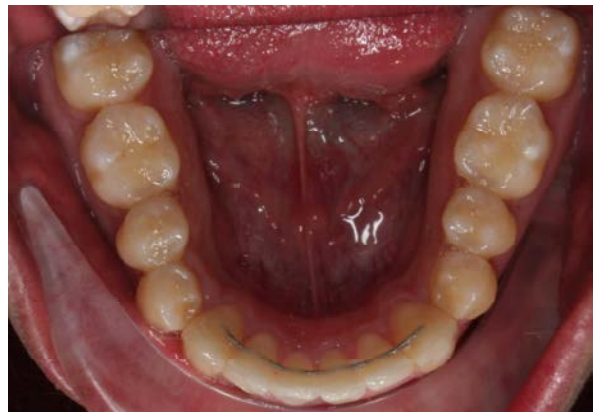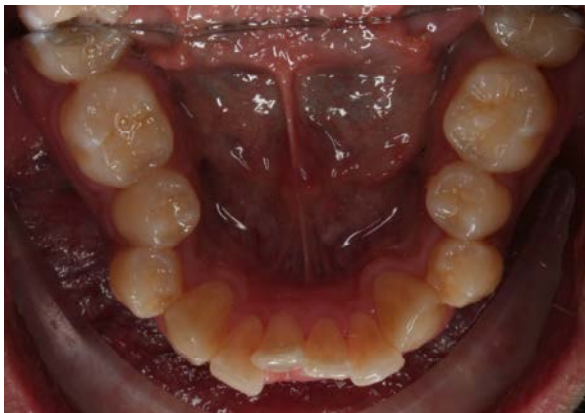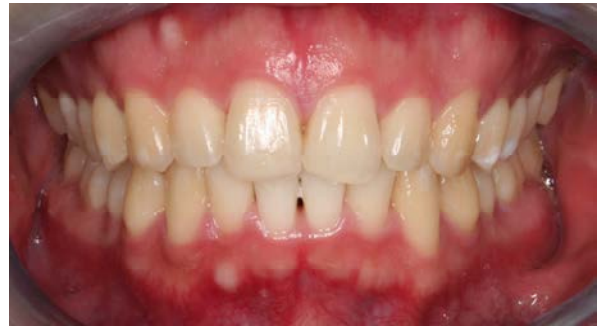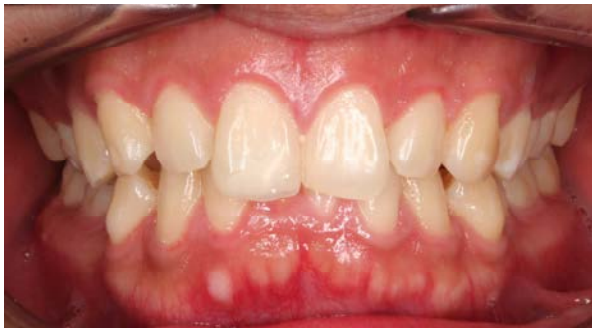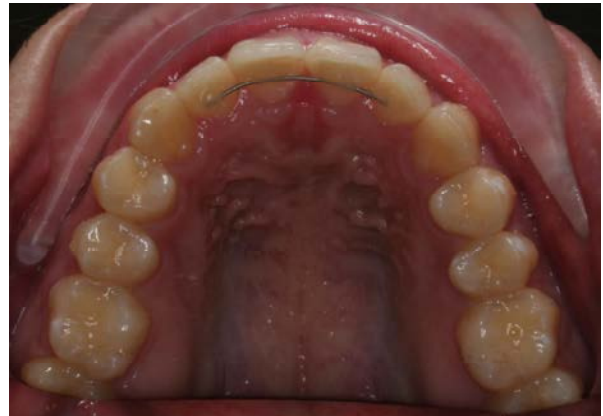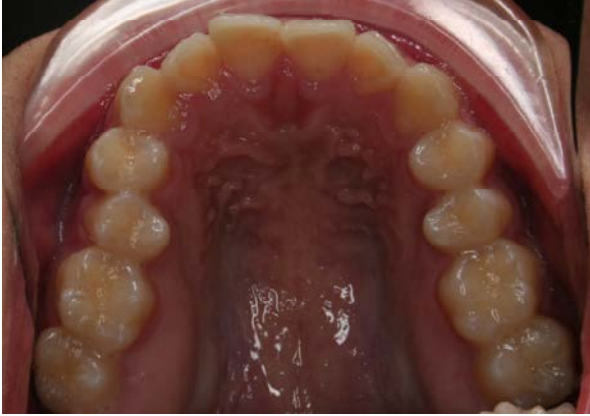Before

After

Lower Crowding / Uprighting Roots with Invisalign®
Treatment Length: 14 months



Treated by Dr. Bella Shen Garnett



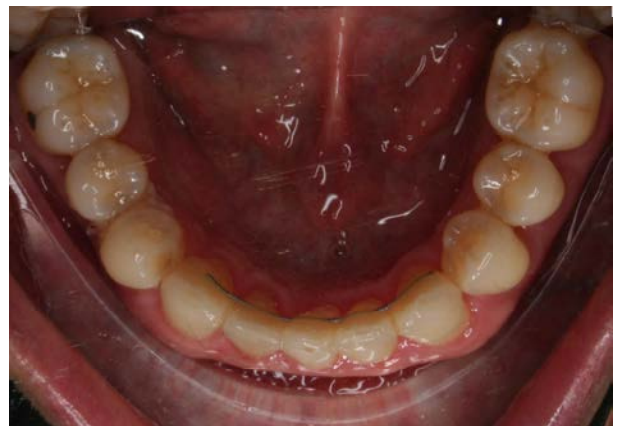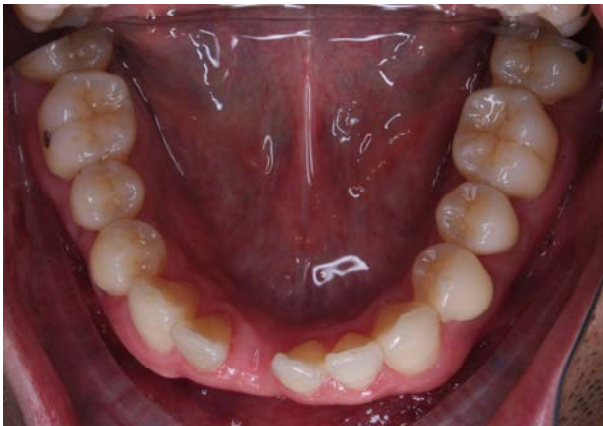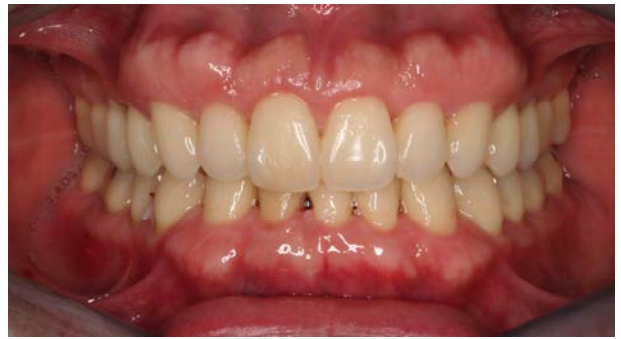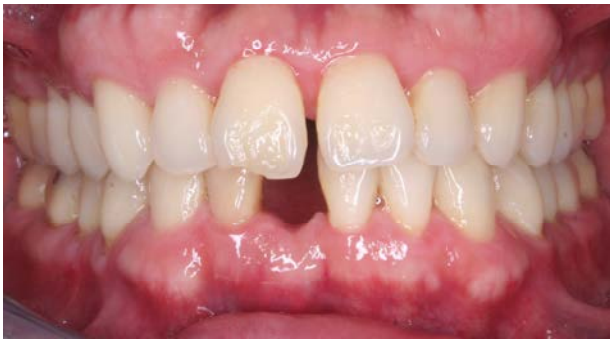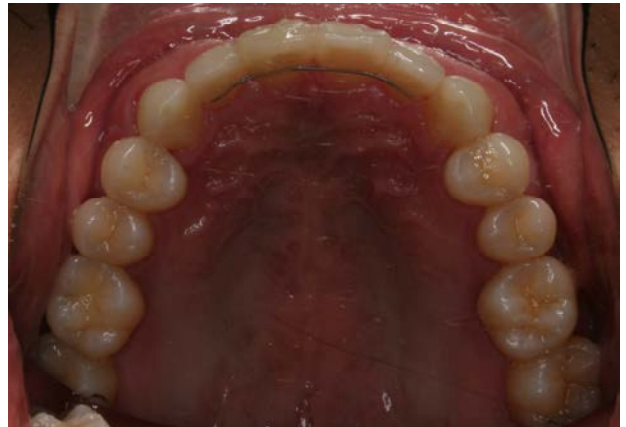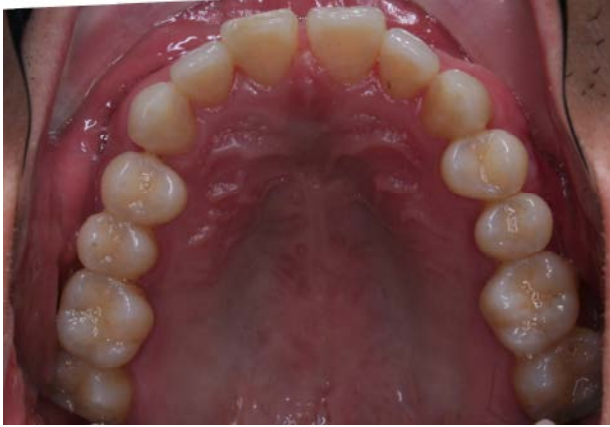Before

After

Crowding / Deep Bite treated with Invisalign®
Treatment Length: 15 months



Treated by Dr. Bella Shen Garnett



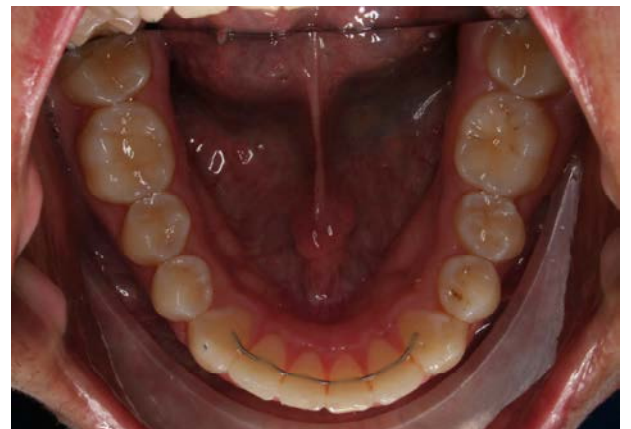
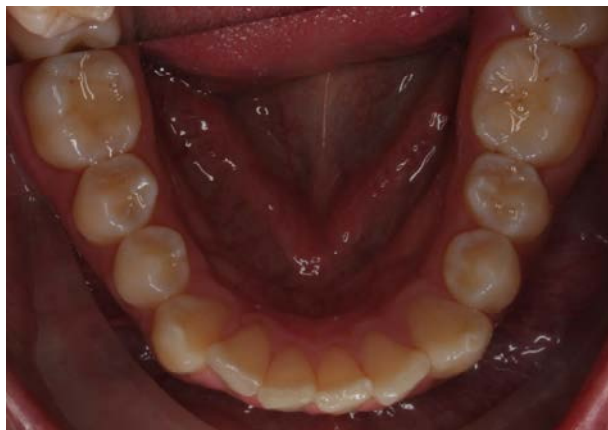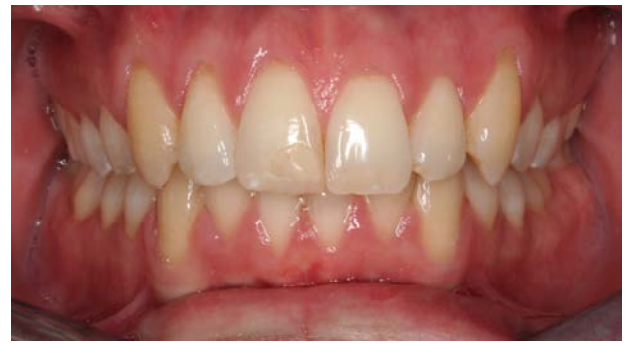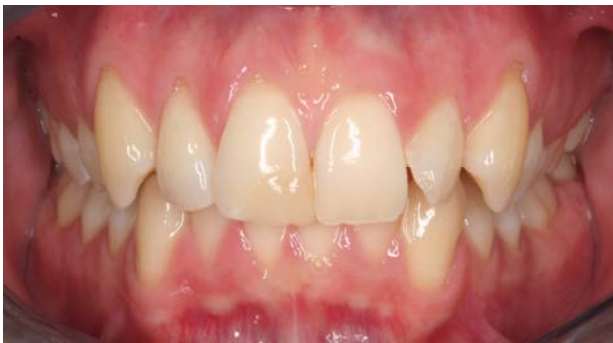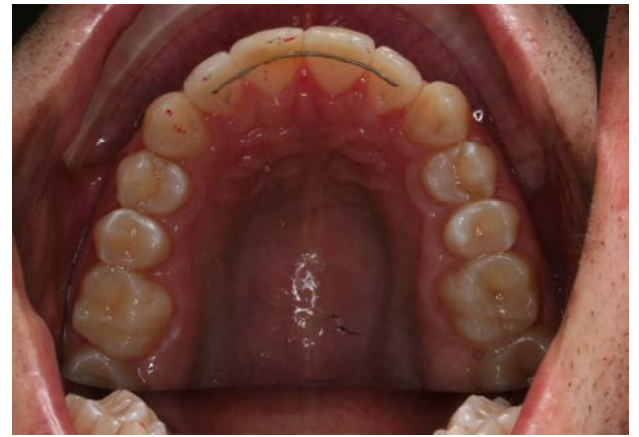
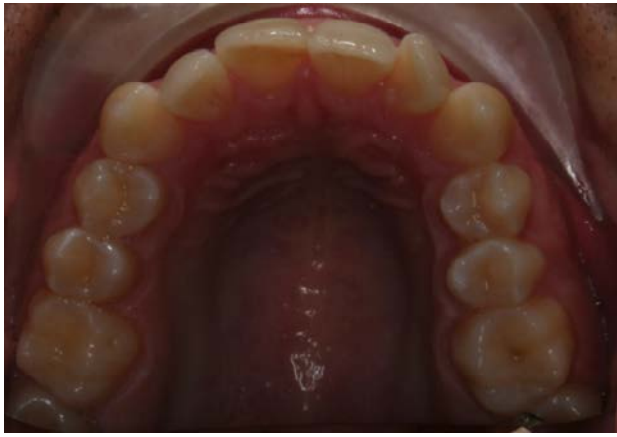Before

After

Missing Lower Incisor and closed space with Invisalign®
Treatment Length: 11 months



Treated by Dr. Bella Shen Garnett



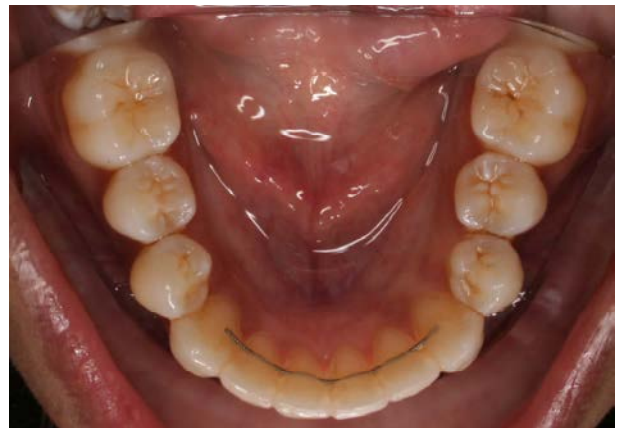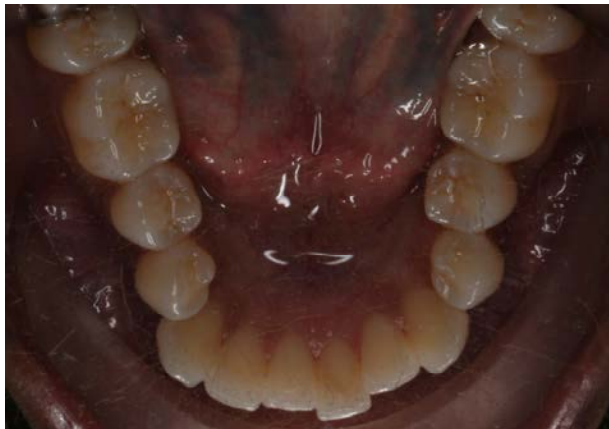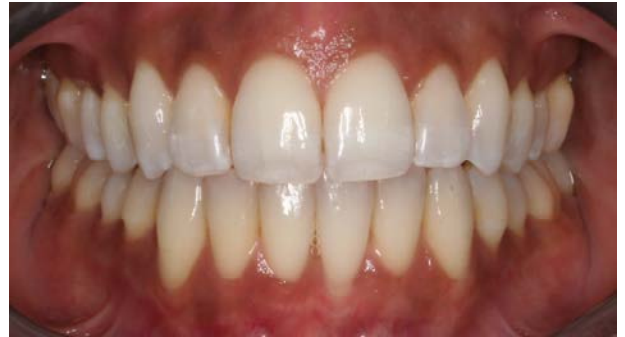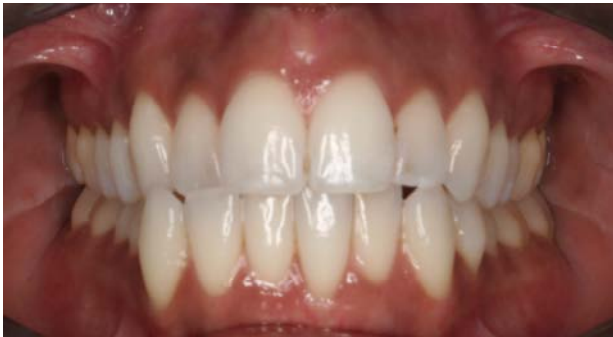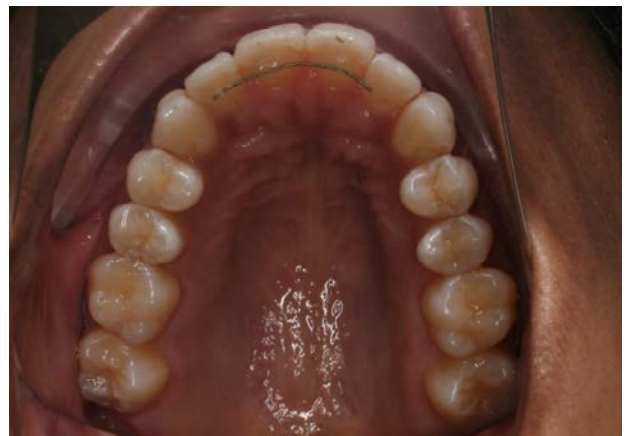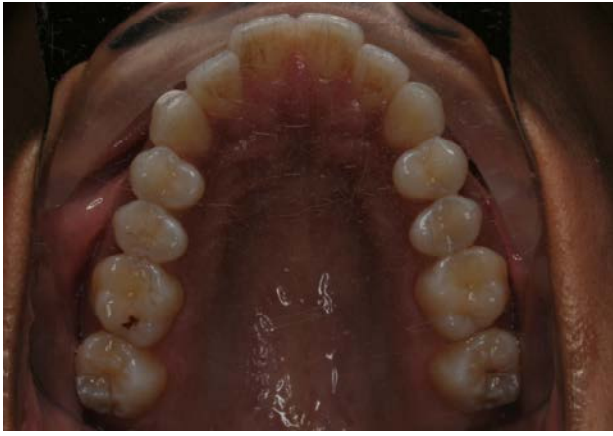Before

After

Crowding with rotated upper left lateral incisor treated with Invisalign®
Treatment Length: 12 months



Treated by Dr. Bella Shen Garnett



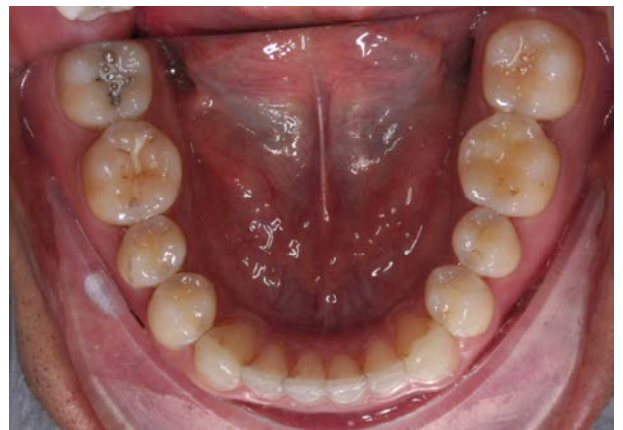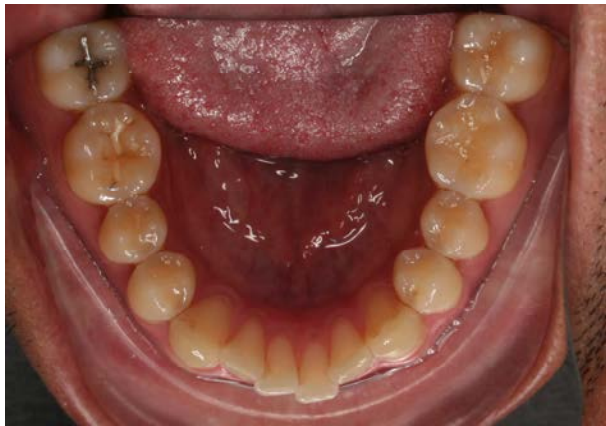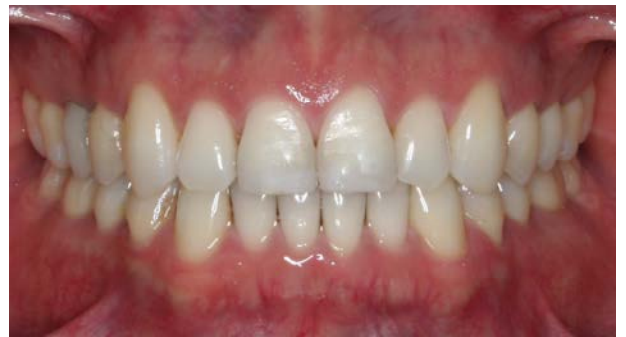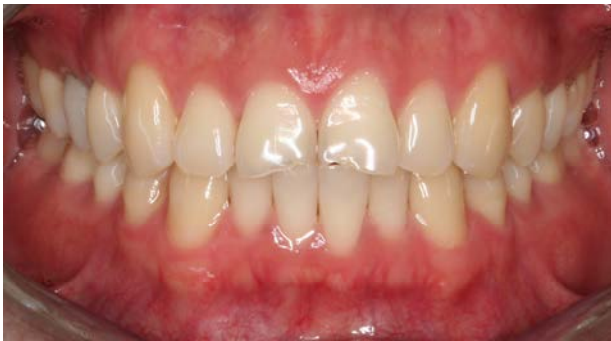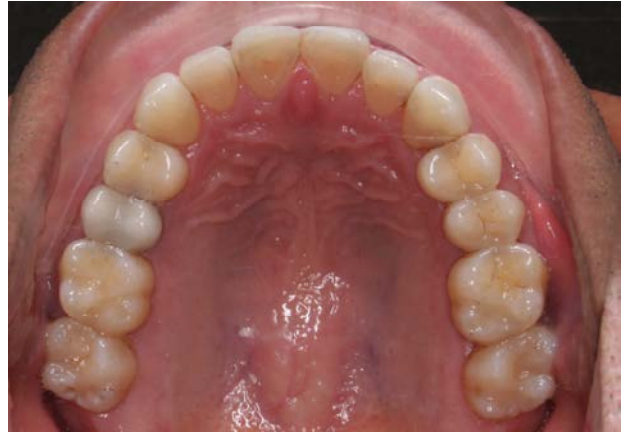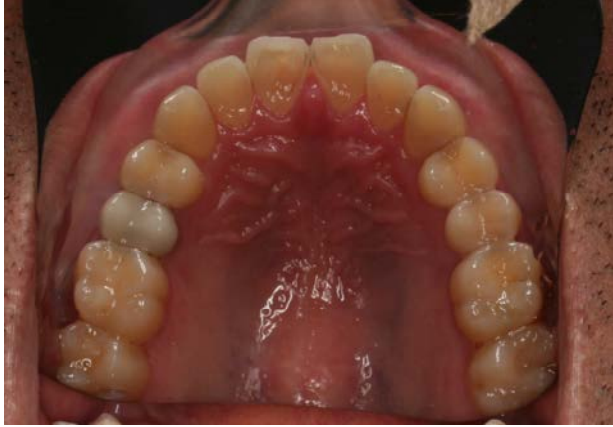Before

After

Partial Anterior Crossbite / Midlines corrected with Invisalign®
Treatment Length: 8 months



Treated by Dr. Bella Shen Garnett



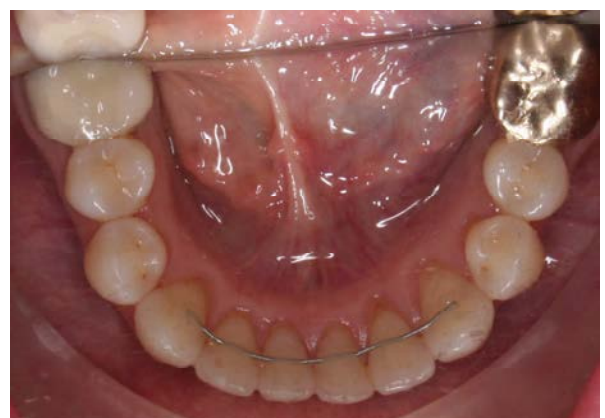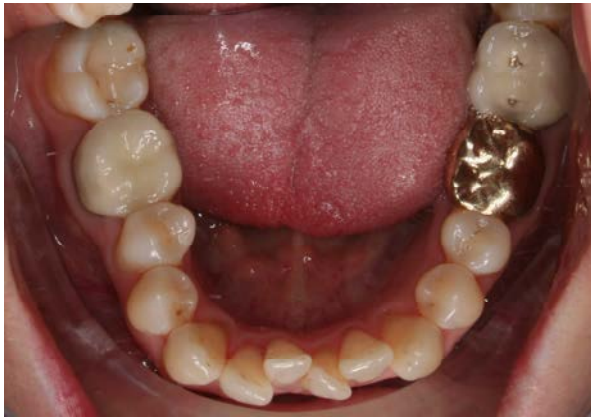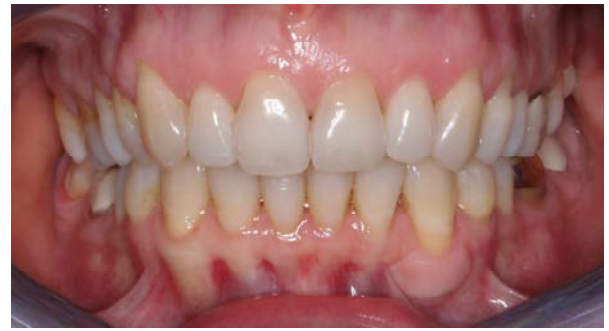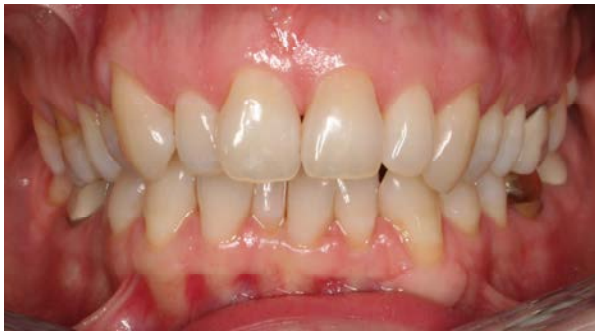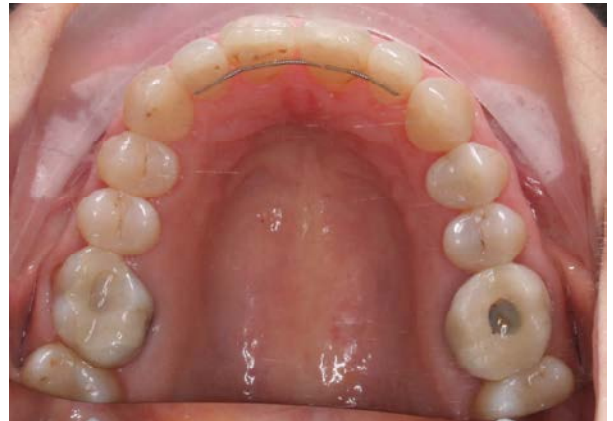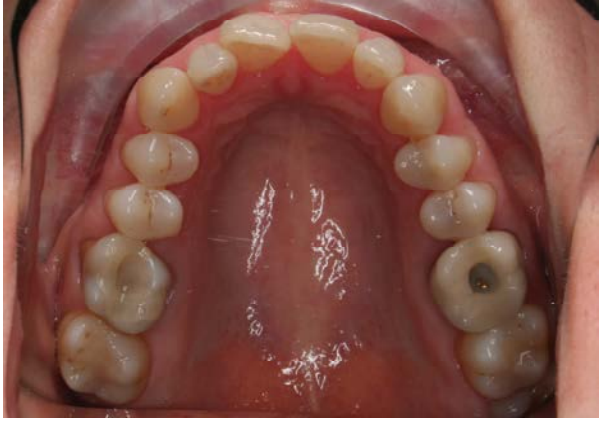
Before

After

Edge to edge bite and severe wear on anterior teeth
Overjet increased and treated with Invisalign[®] with Class III elastics.
Dentist placed Bonding on anterior teeth
Treatment Length: 13 months



Treated by Dr. Bella Shen Garnett



Before

After

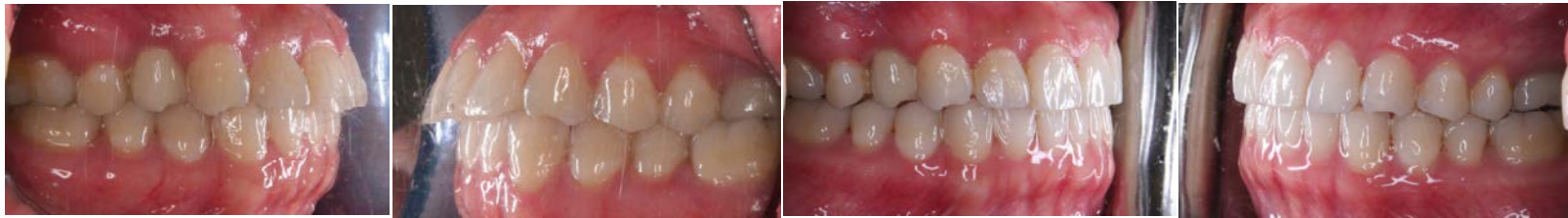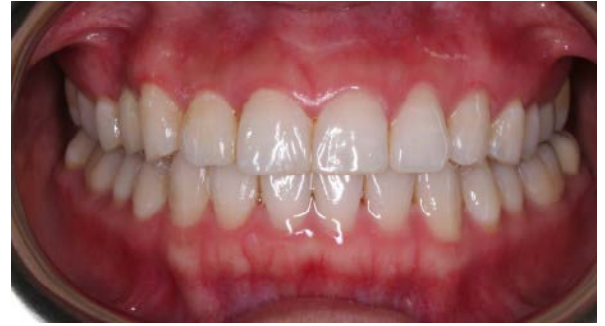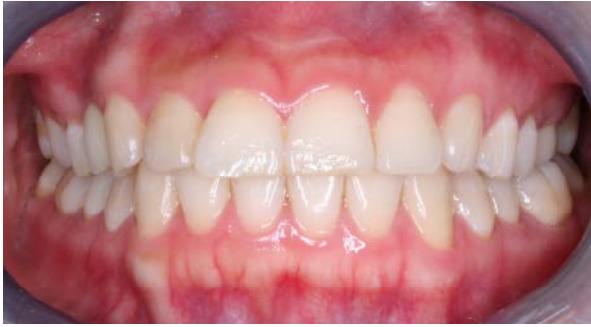Invisalign® treated with severe crowding
Treatment Length: 19 months



Treated by Dr. Bella Shen Garnett

Intial

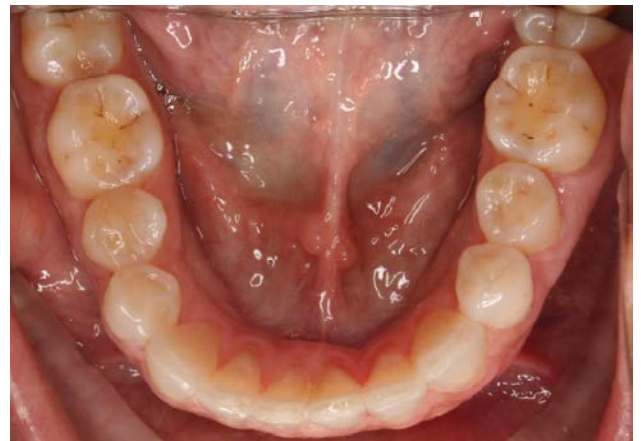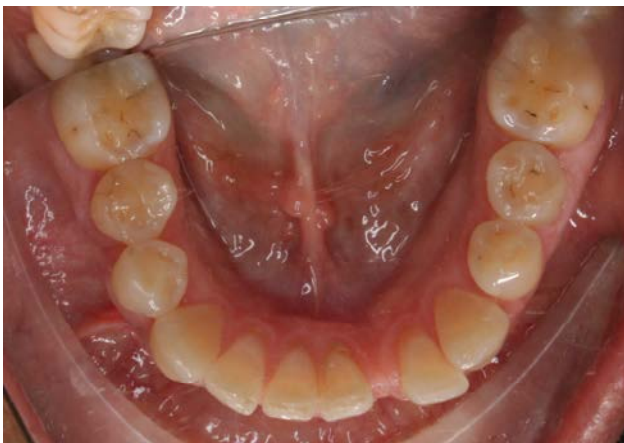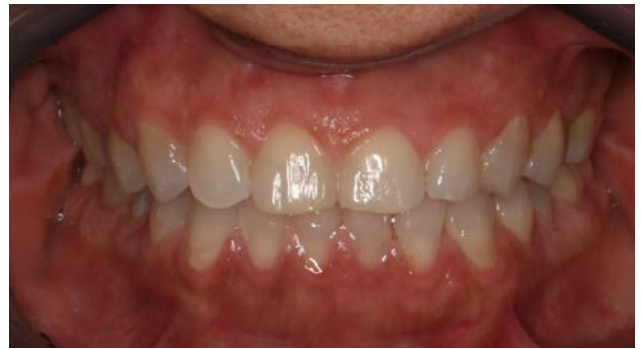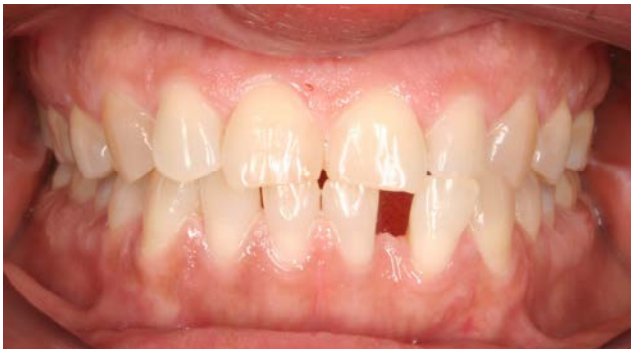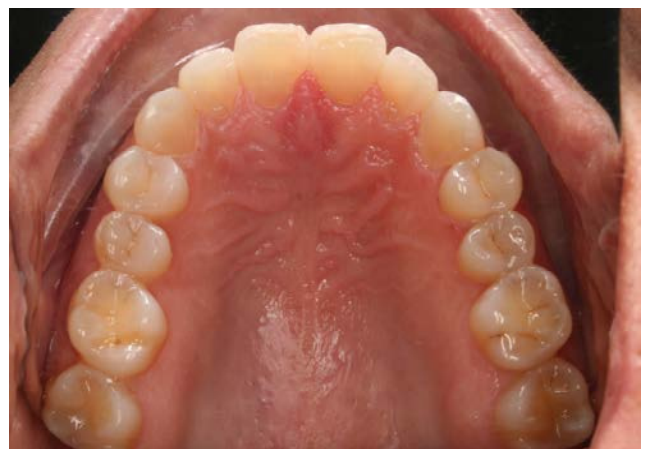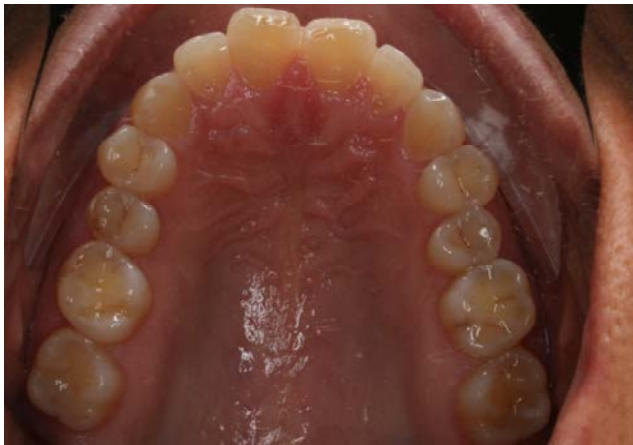Final



Dental Protrusion treated non-extraction with Invisalign®
Treatment Length: 6 months



Treated by Dr. Bella Shen Garnett



Before

After

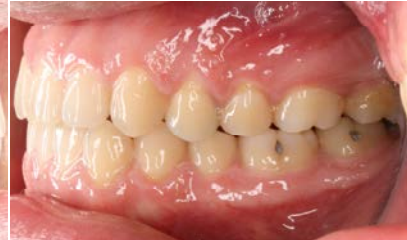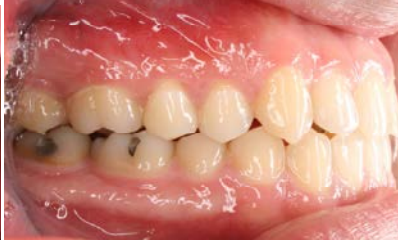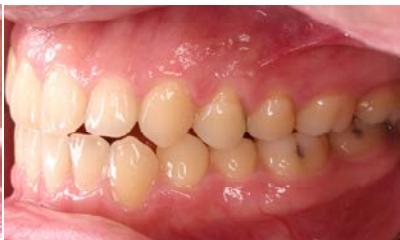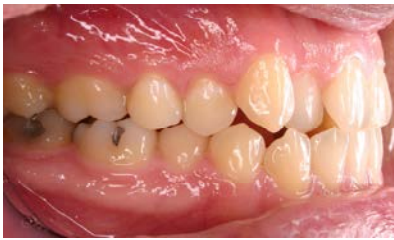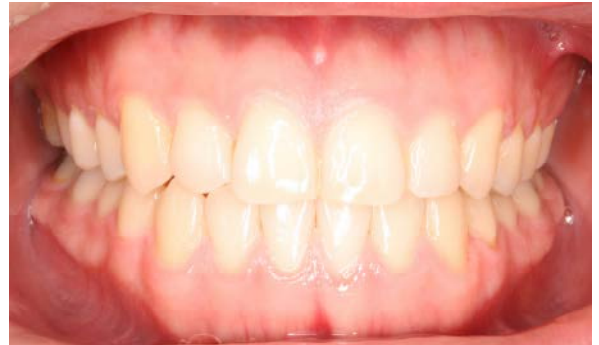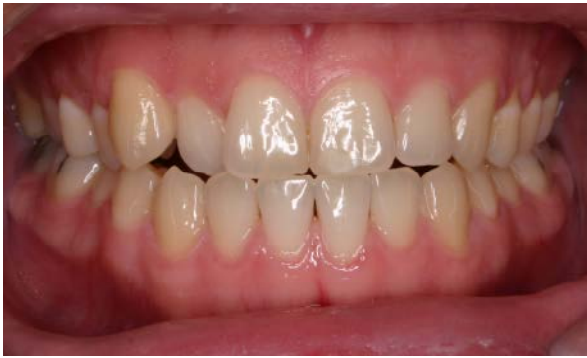Severe lower spacing closed by Invisalign®
Treatment Length: 12 months



Treated by Dr. Bella Shen Garnett

Intial

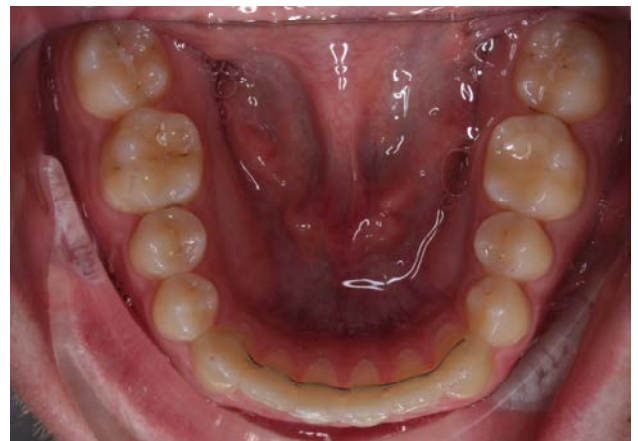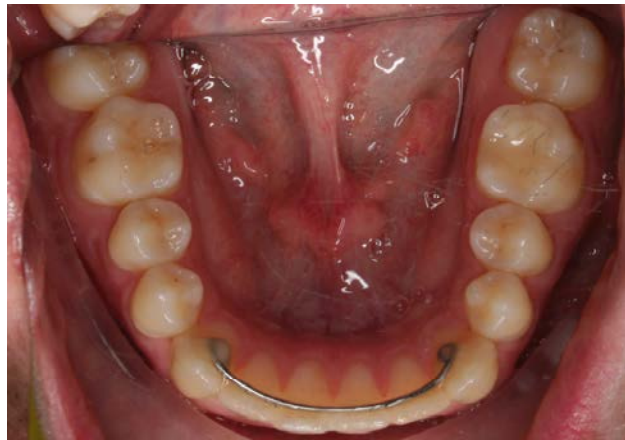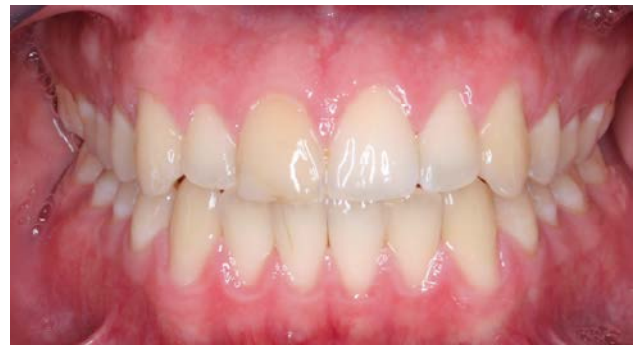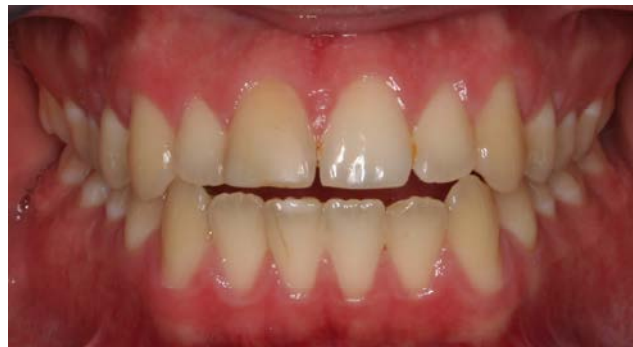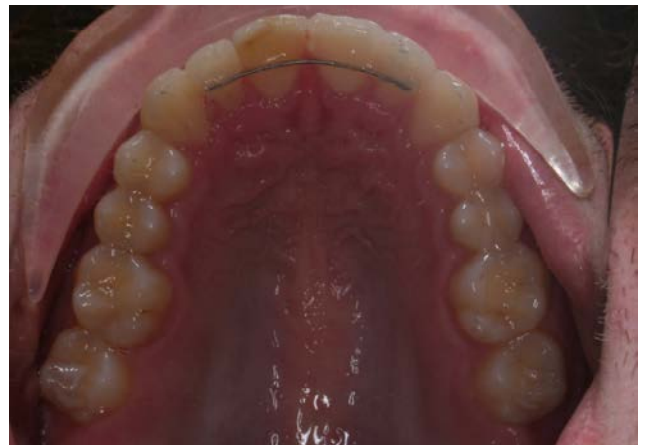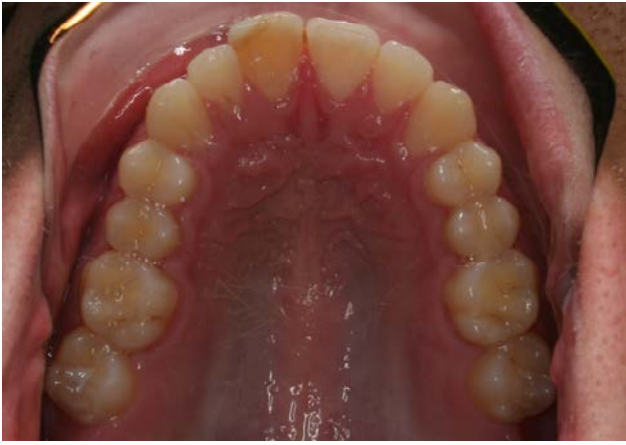Final



Edge to edge bite and Class treated with Class III elastics and Invisalign®
No IPR was done (No filing of the teeth)
Treatment Length: 12 months



Treated by Dr. Bella Shen Garnett



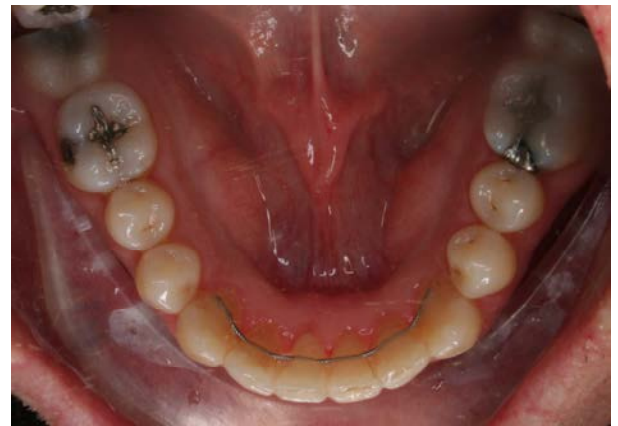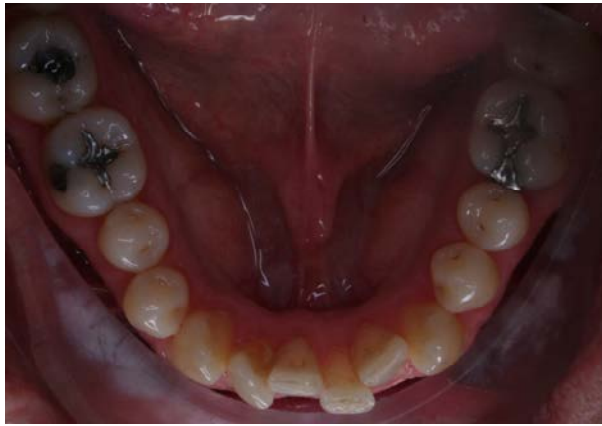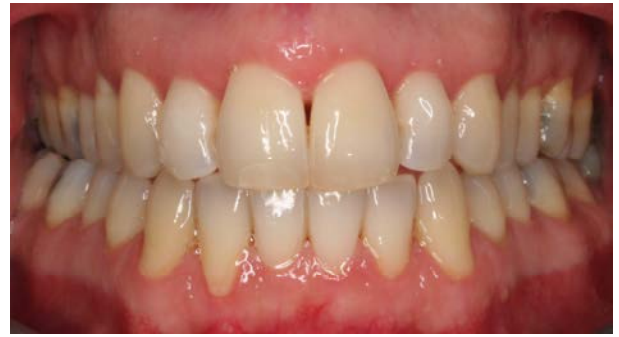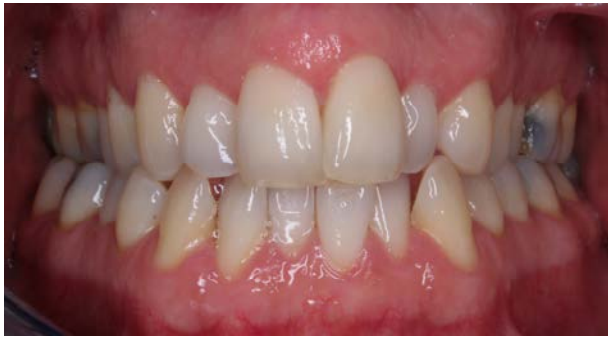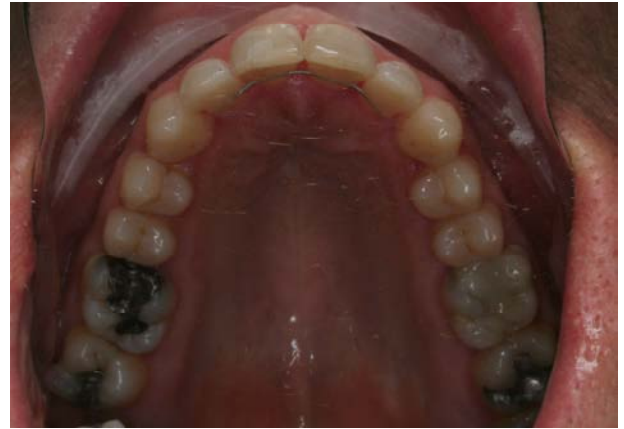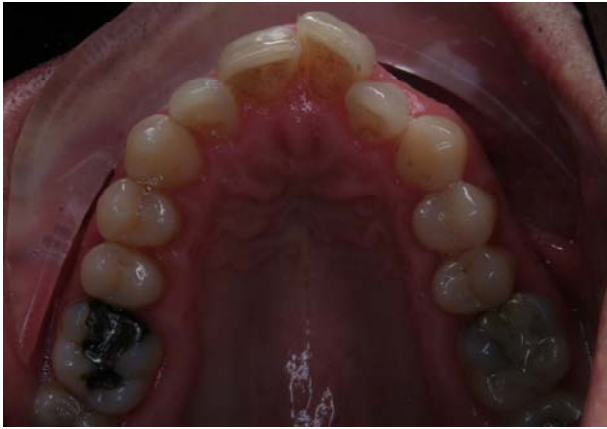Before

After

Open Bite Treated by Invisalign®
Treatment Length: 10 months



Treated by Dr. Bella Shen Garnett



Before

After

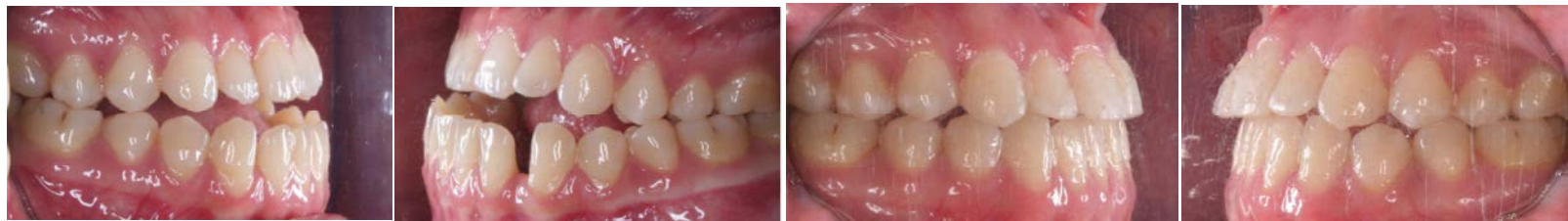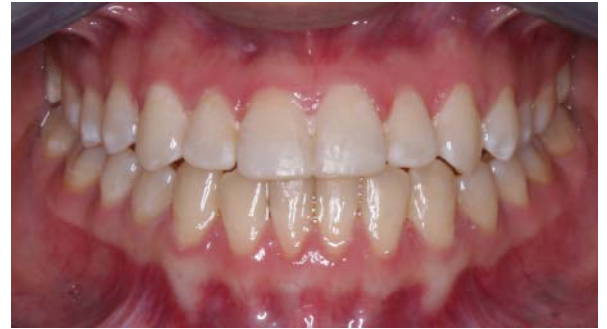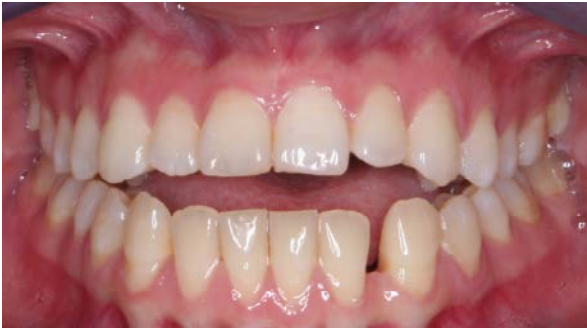Severe upper and lower crowding treated by Invisalign®
Treatment Length: 10 Months



Treated by Dr. Bella Shen Garnett

Intial

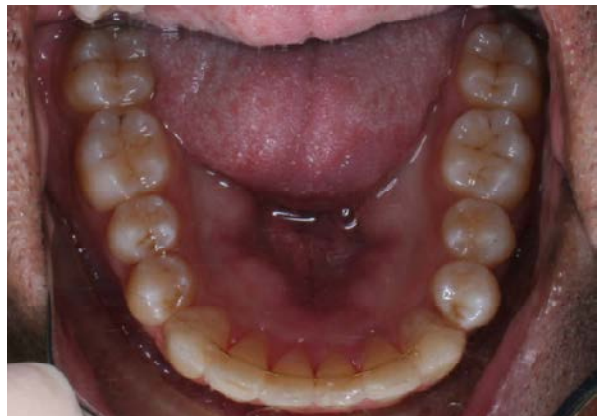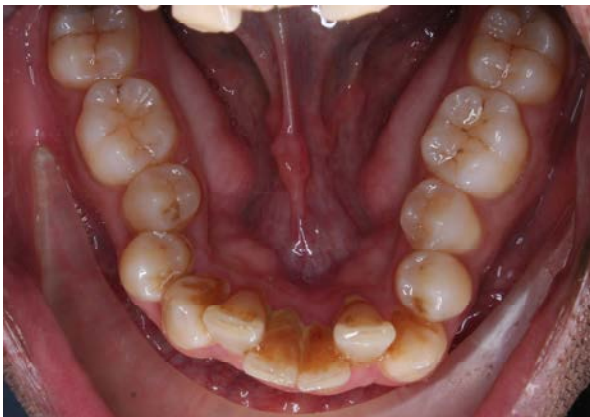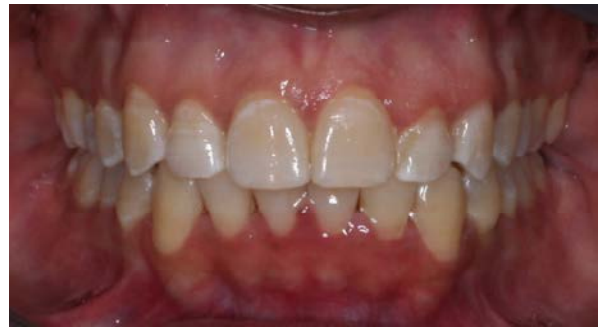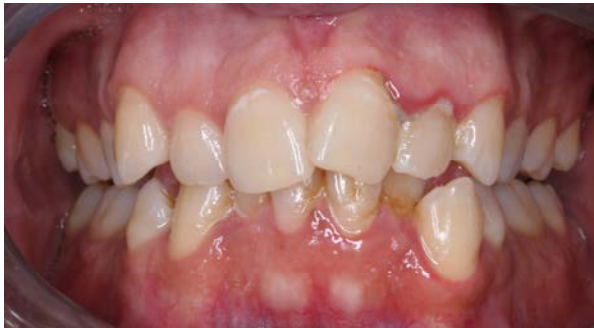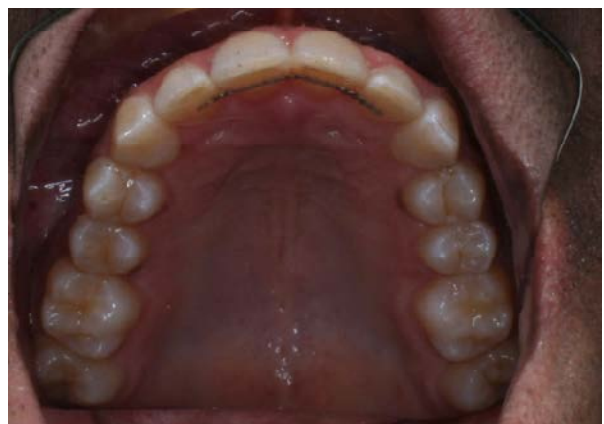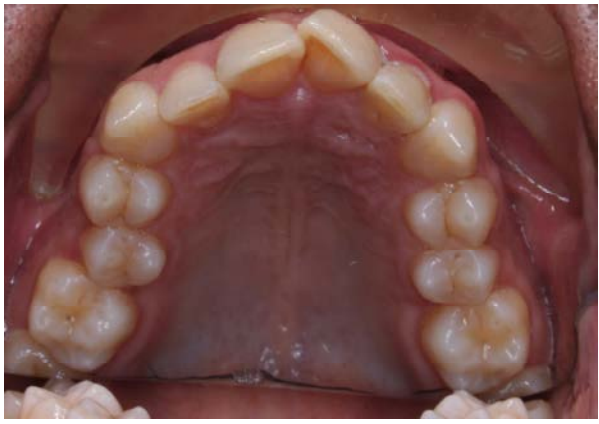
Final



20 Year Old Female with a Class III Malocclusion (Underbite with an Open Bite)
Treated with Invisalign® and Class III elastics (NO SURGERY NEEDED)
Treatment Length: 10 Months



Treated by Dr. Bella Shen Garnett



Before

After

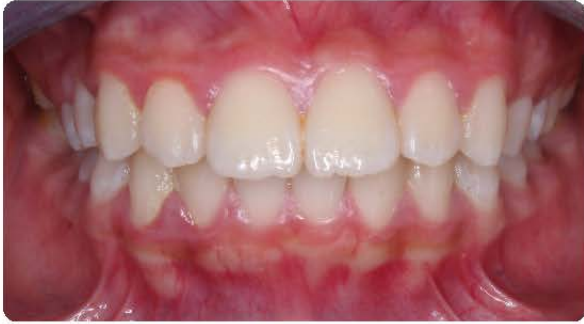Severe deep bite and severe crowding
Treated Non-Extraction with Invisalign®

Treatment Length: 15 Months

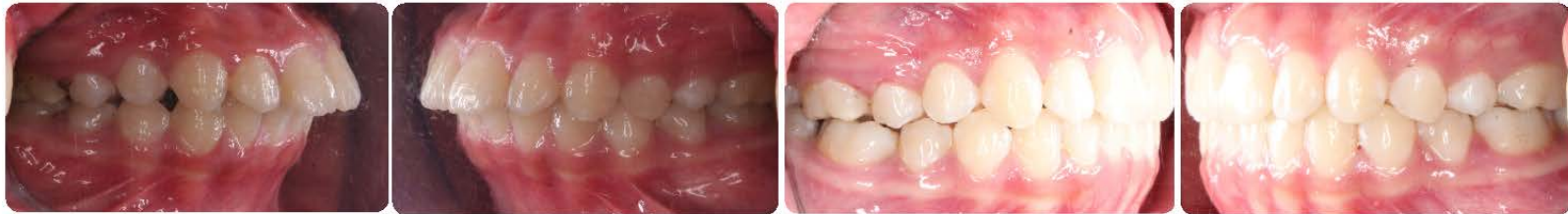
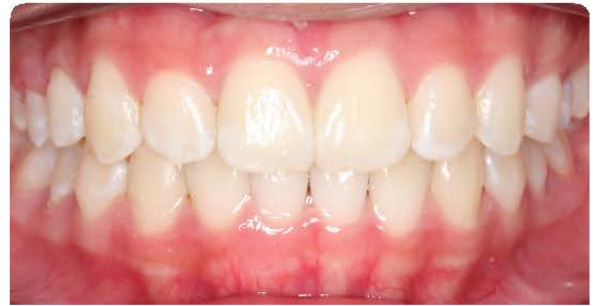
Treated by Dr. Bella Shen Garnett

Initial



Final



14 year old Female presents Class II on the right and Class I on the left.

Dental Protrusion treated with Invisalign Teen[®].

Distalized the teeth on the right side to correct midline and bite.

NON-EXTRACTION

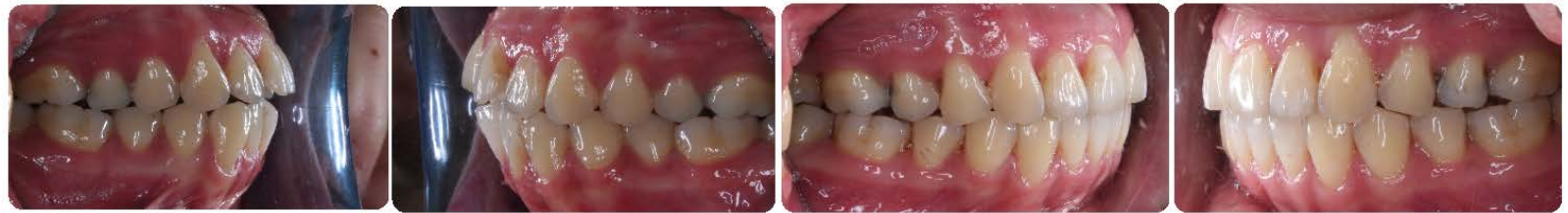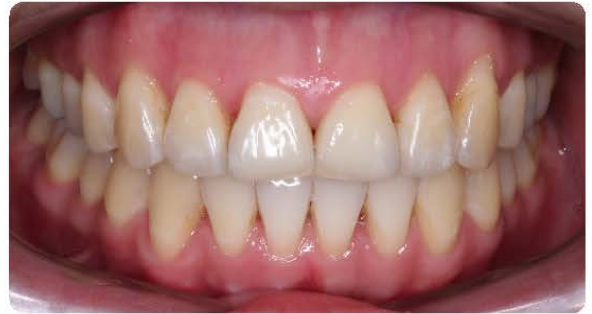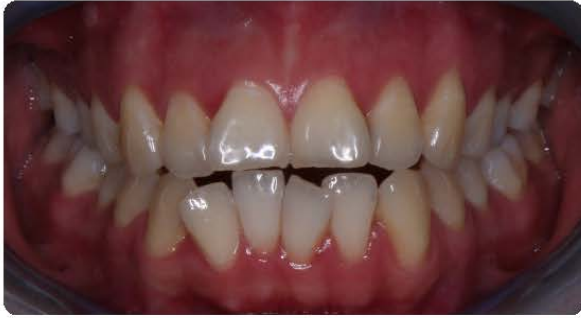Treatment Length: 24 months



Treated by Dr. Bella Shen Garnett

Initial

Final

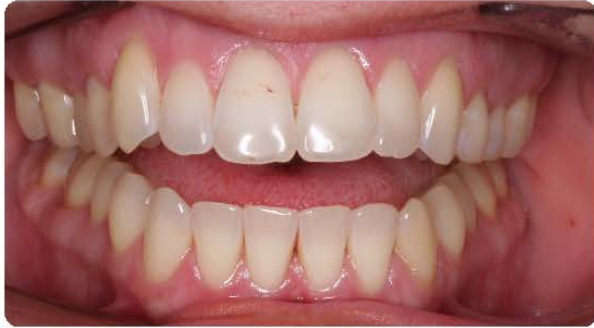

22 year old Female
Protrusion, open bite and crowding treated with Invisalign®
Non-Extraction
Treatment Length: 17 Months

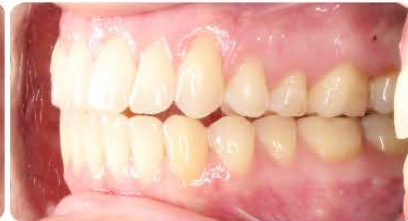
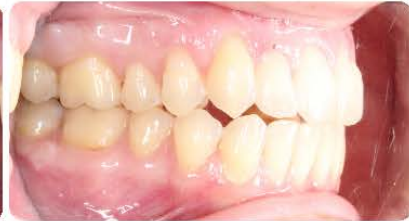
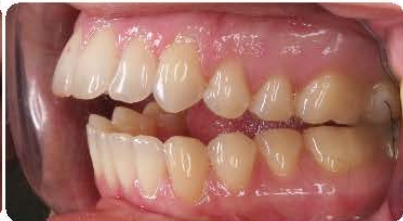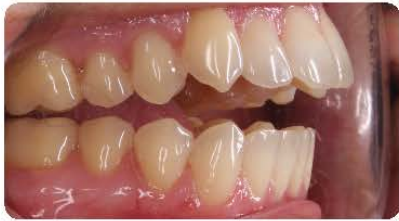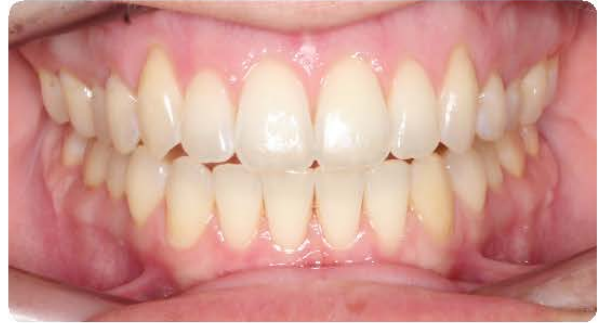Treated by Dr. Bella Shen Garnett

Initial



Final

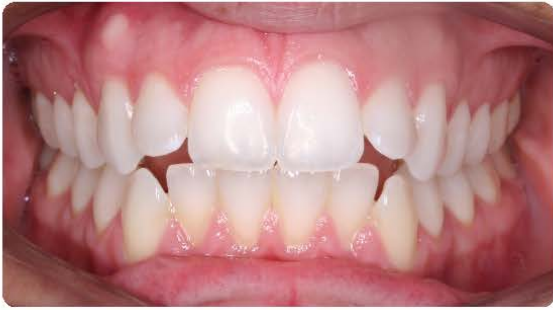

31 year old Female
Openbite treated with Invisalign® and Class II elastics and TADS
NO JAW SURGERY
Treatment Length: 20 months

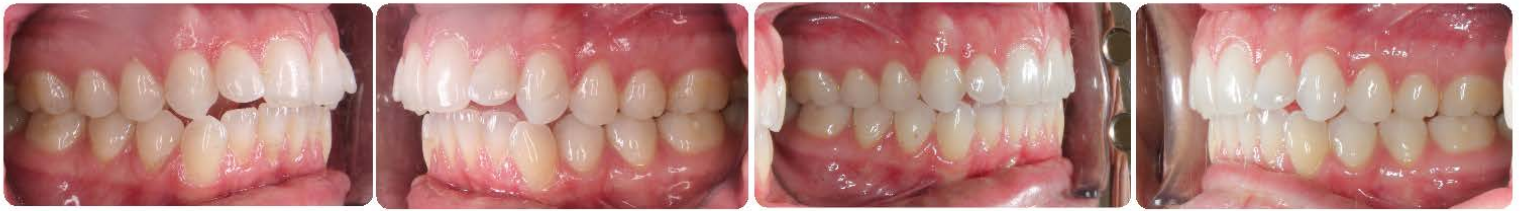
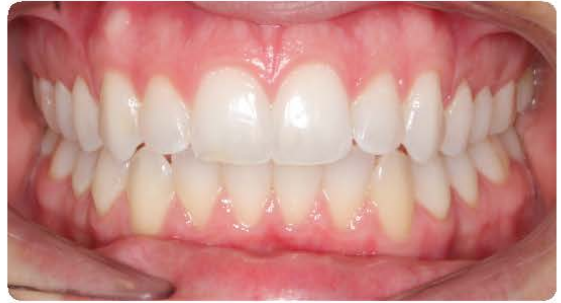
Treated by Dr. Bella Shen Garnett

Initial



Final

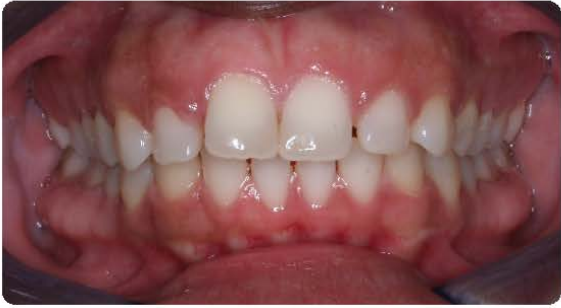

25 year old Female
Crowding and Openbite treated with Invisalign®
Treatment Length: 9 months

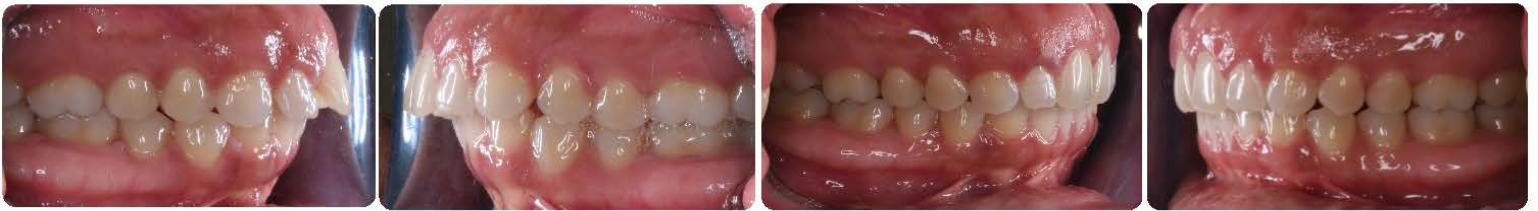
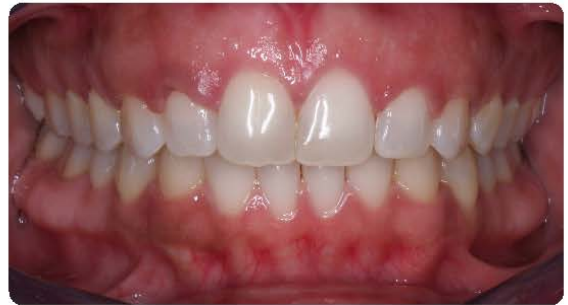
Treated by Dr. Bella Shen Garnett

Initial



Final

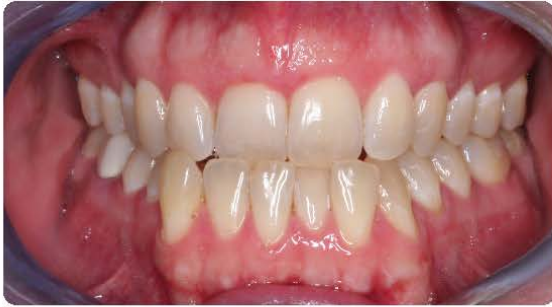

33 year old Female
Spacing and Protrusion treated with Invisalign® and Class II elastics
Treatment Length: 14 months

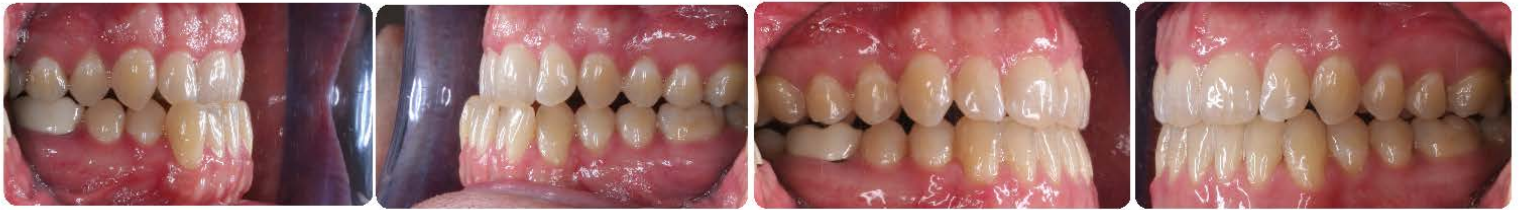
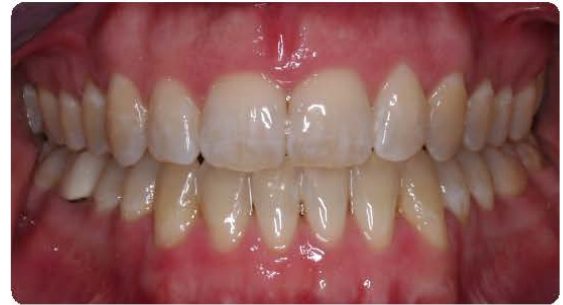
Treated by Dr. Bella Shen Garnett

Initial



Final

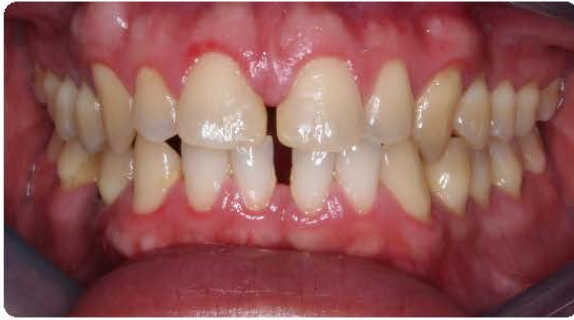

44 year old Male
Class III, Edge to Edge bite, Anterior Crossbite and Mild Crowding treated with
Invisalign® and Class III elastics
Treatment Length: 18 months

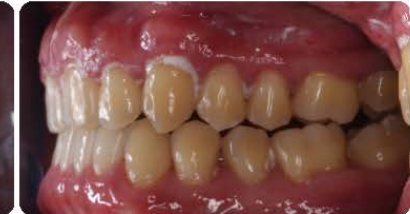
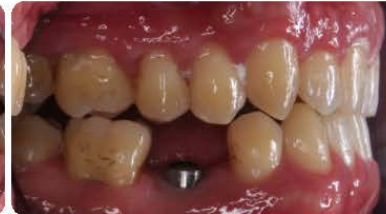
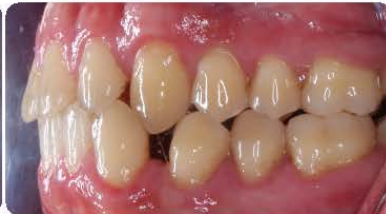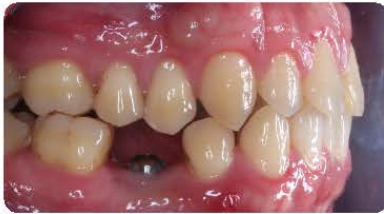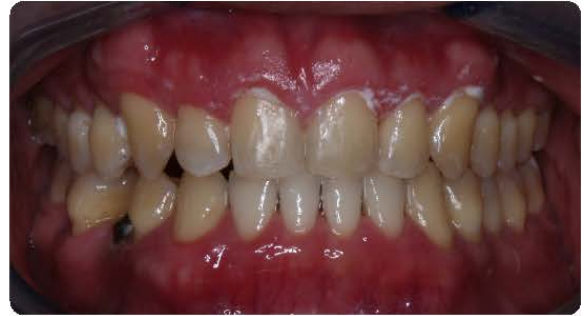Treated by Dr. Bella Shen Garnett

Initial



Final



37 year old Male

Severe Spacing, Mild Overbite, and Midlines are shifted to the left. Removed bonding between upper front teeth and closed space

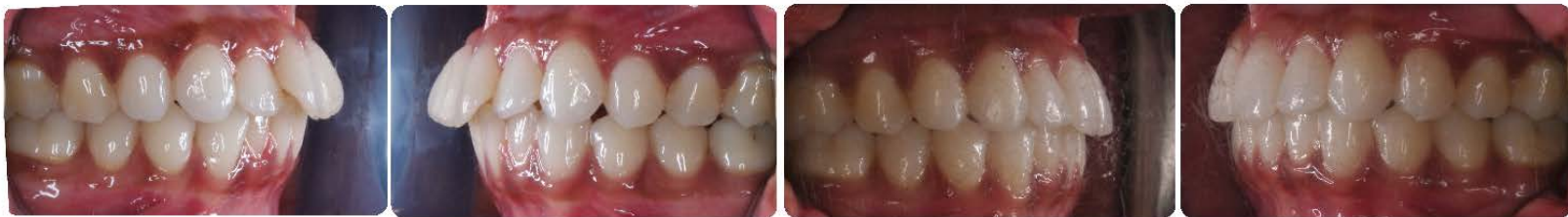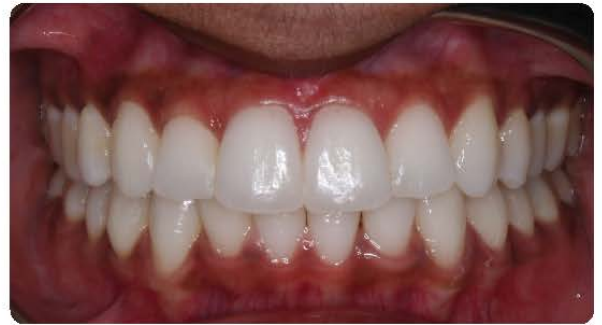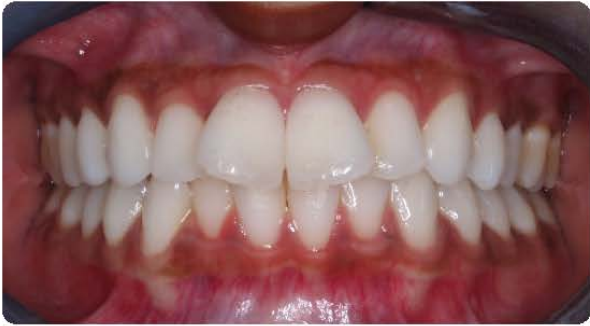Treatment Length: 16 months



Treated by Dr. Bella Shen Garnett

Initial

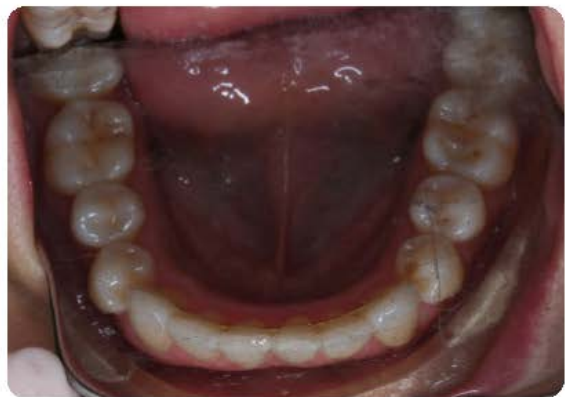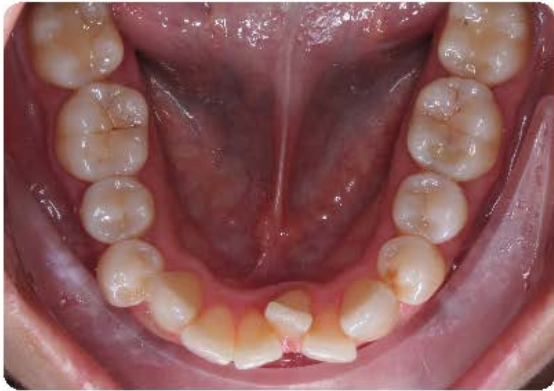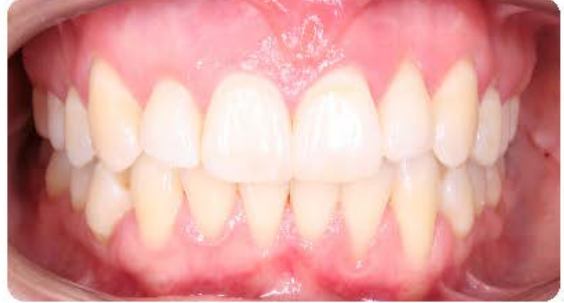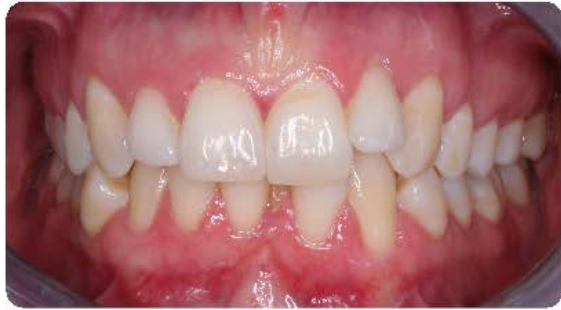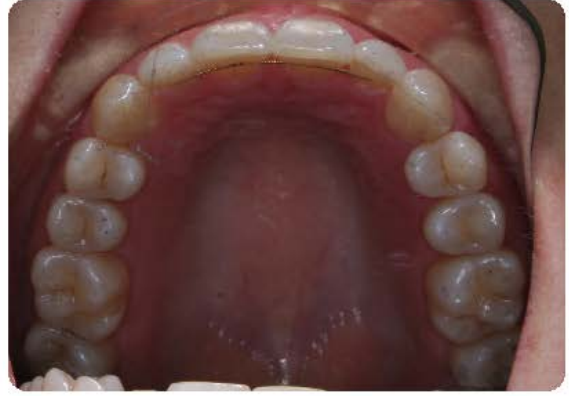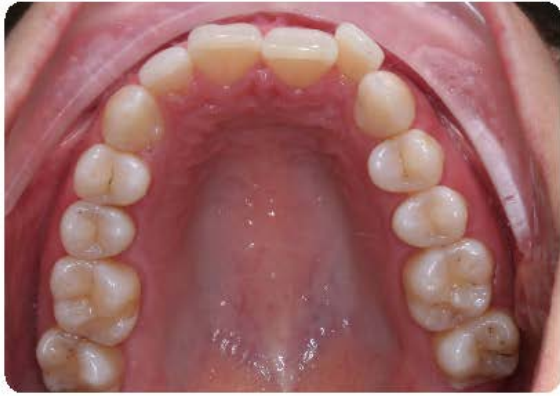Final



32 year old Female
Severe Crowding and Protrusion treated with Invisalign®
Treatment Length: 20 months



Treated by Dr. Bella Shen Garnett



Initial

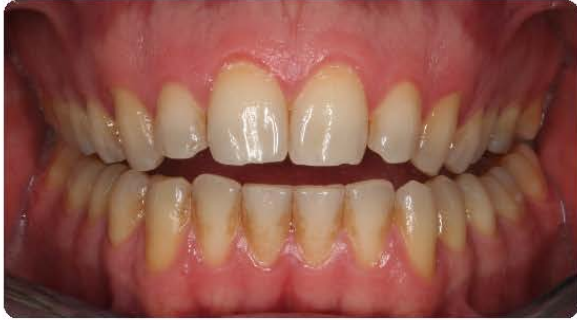Final

36 year old Female
Severe Crowding, Overjet, and Overbite treated with Invisalign®
Treatment Length: 22 months

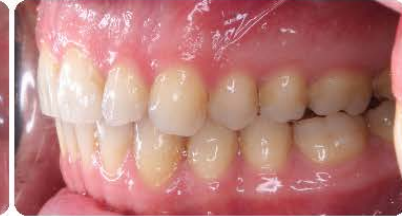
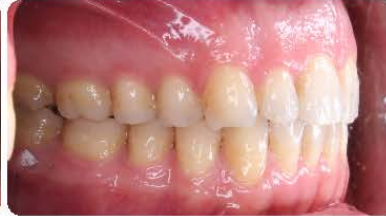
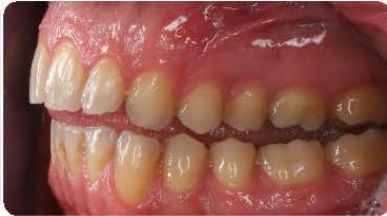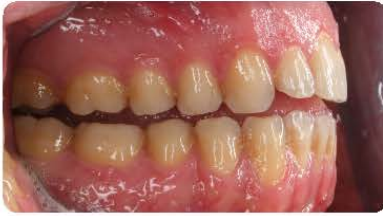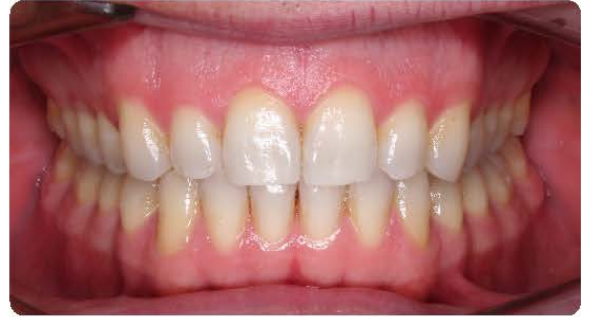Treated by Dr. Bella Shen Garnett

Initial



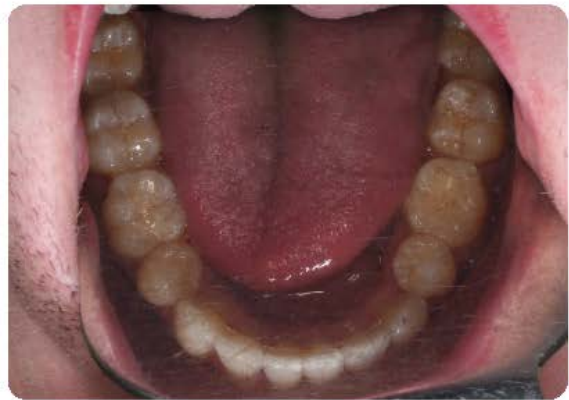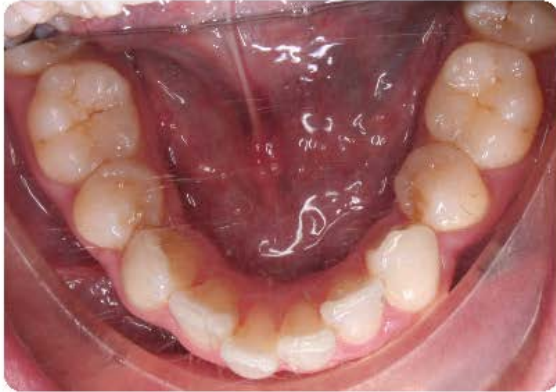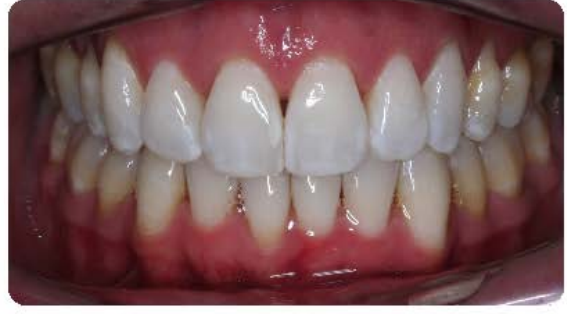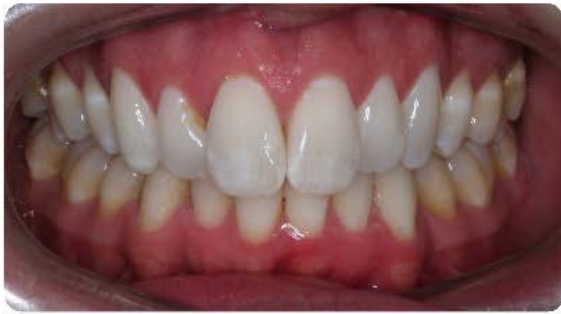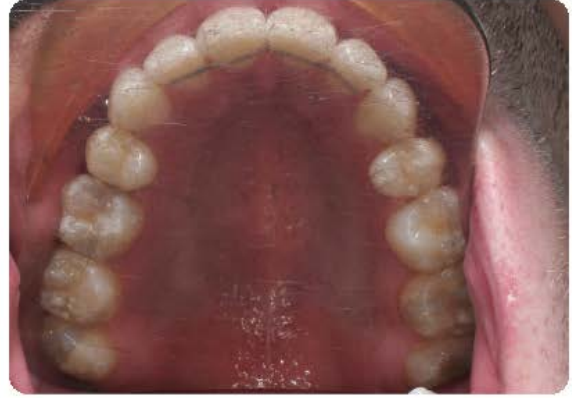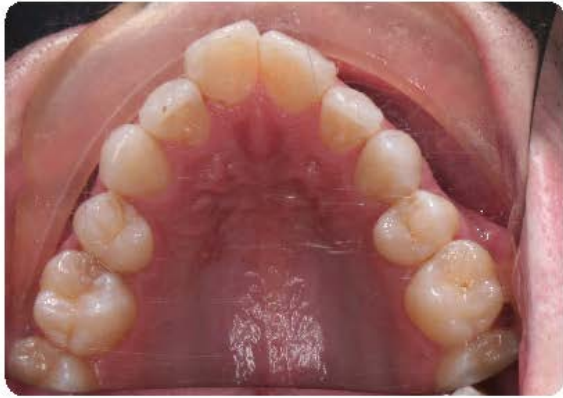Final



38 year old Male
Openbite treated with Invisalign®
Treatment Length: 14 months



Treated by Dr. Bella Shen Garnett



Initial

Final

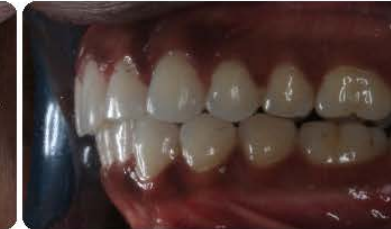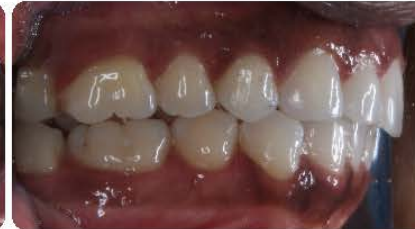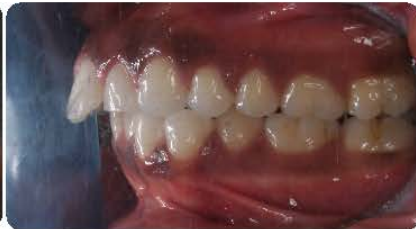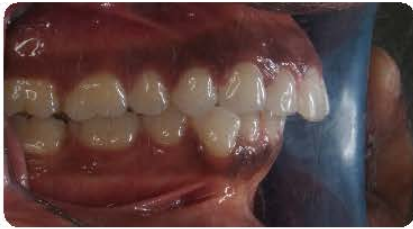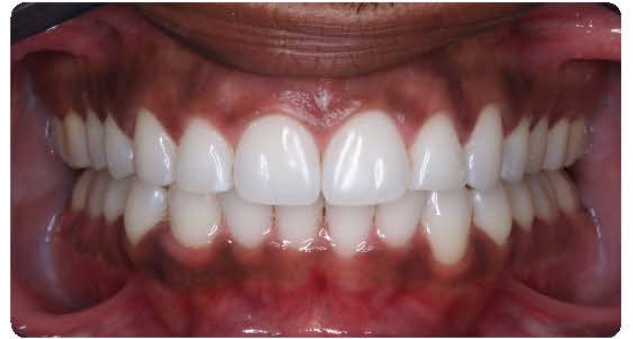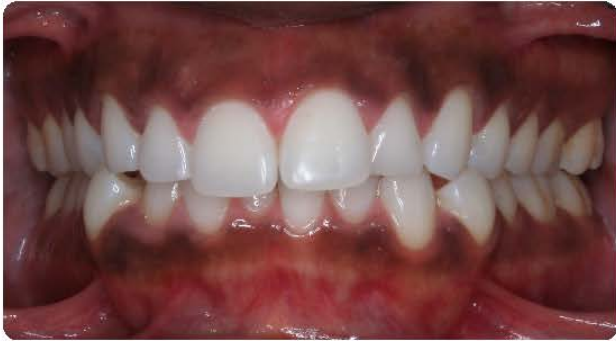Narrow Arches and Crowding treated with Invisalign® and Class II elastics
30 year old Male
Treatment Length: 17 months



Treated by Dr. Bella Shen Garnett

Initial

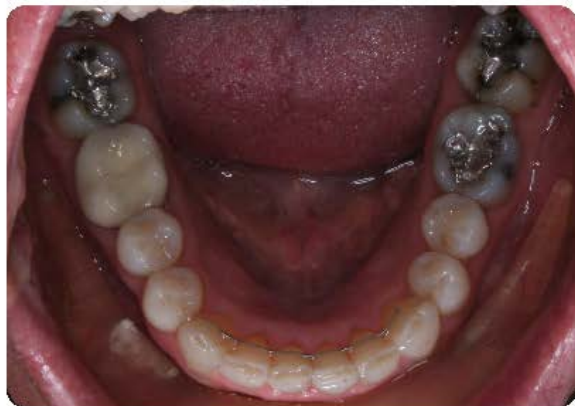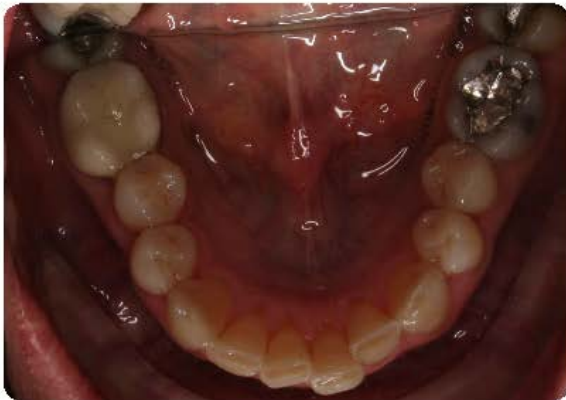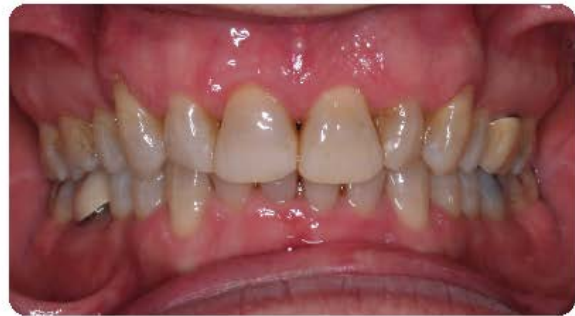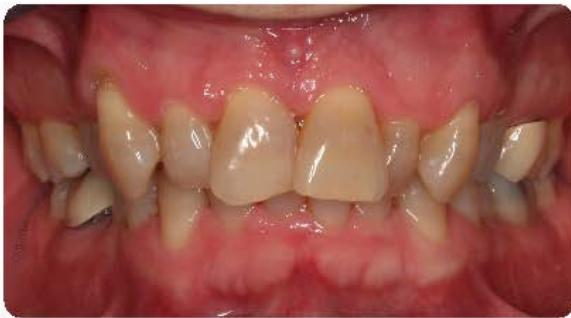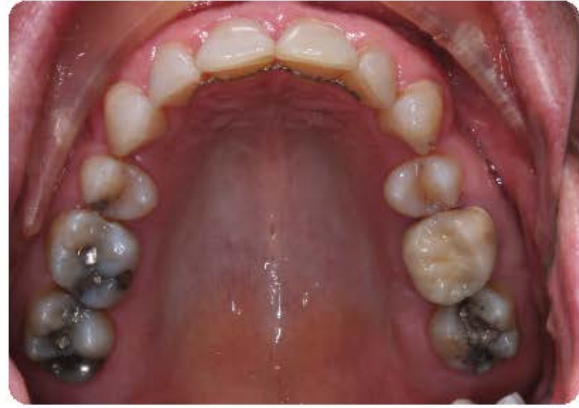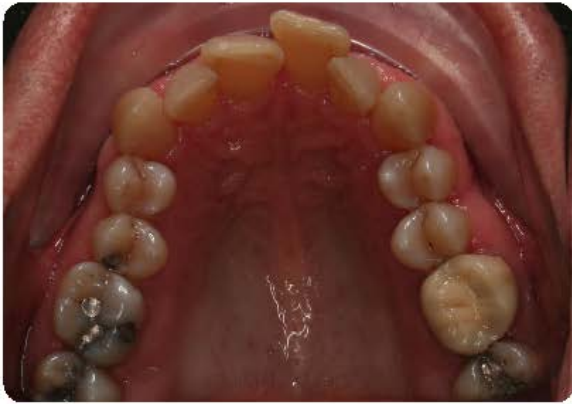Final



Overbite, Overjet and Crowding treated with Invisalign®
26 year old Male
Treatment Length: 11 months



Treated by Dr. Bella Shen Garnett



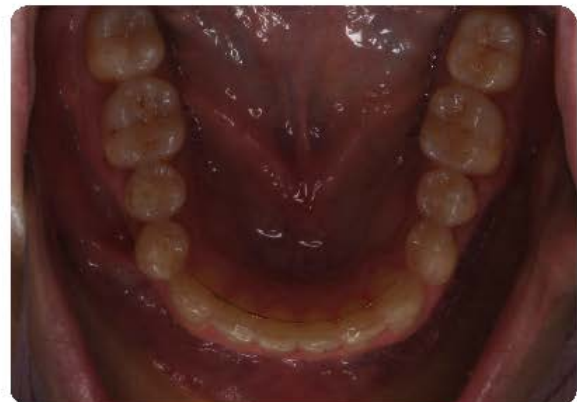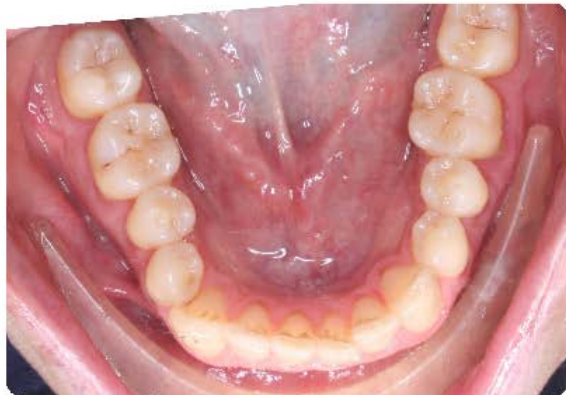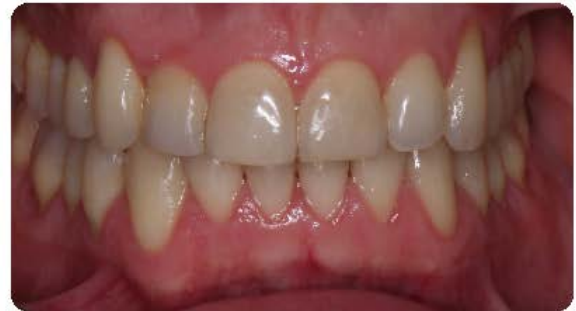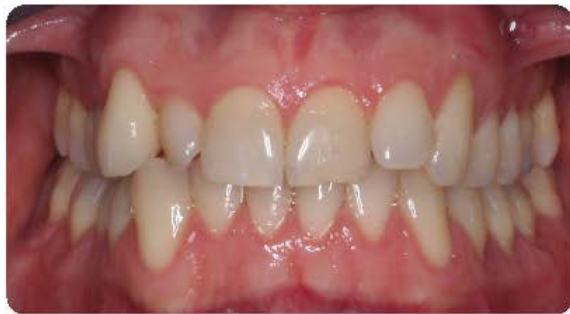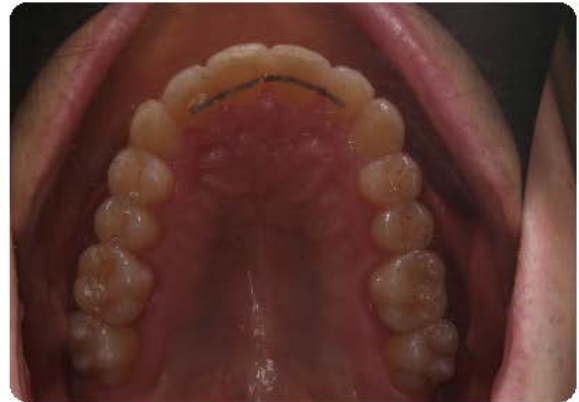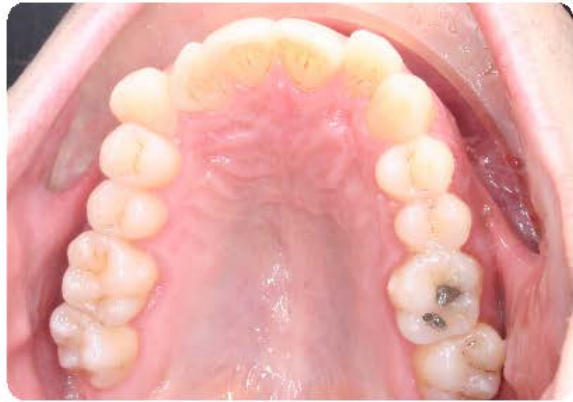Initial

Final

51 year old Male
Full cusp Class II Deep Bite treated with Invisalign® and Class II elastics
Extraction of Teeth #5, 12
Treatment Length: 22 months



Treated by Dr. Bella Shen Garnett



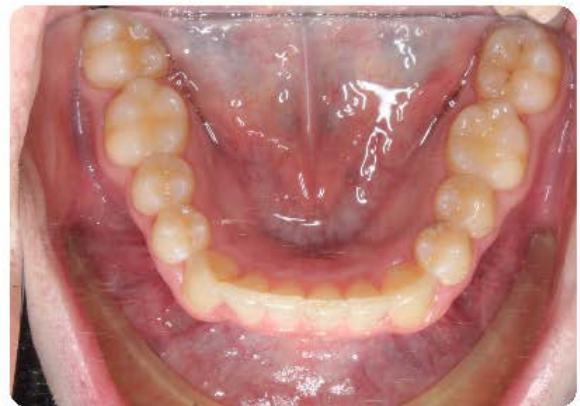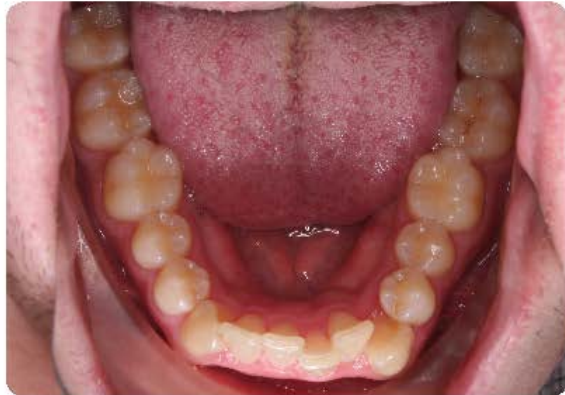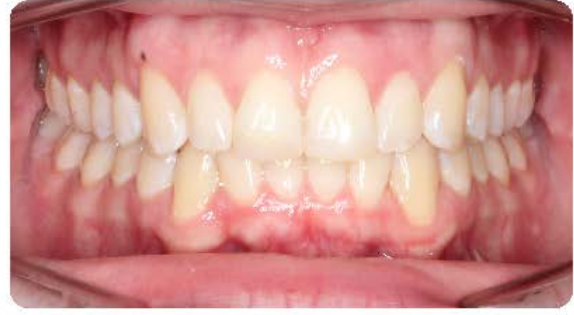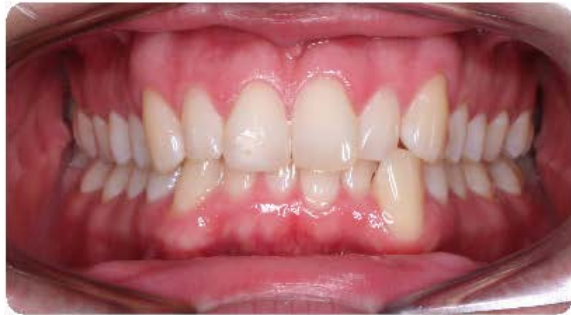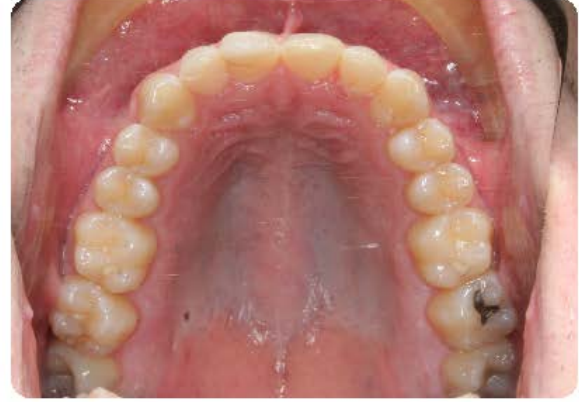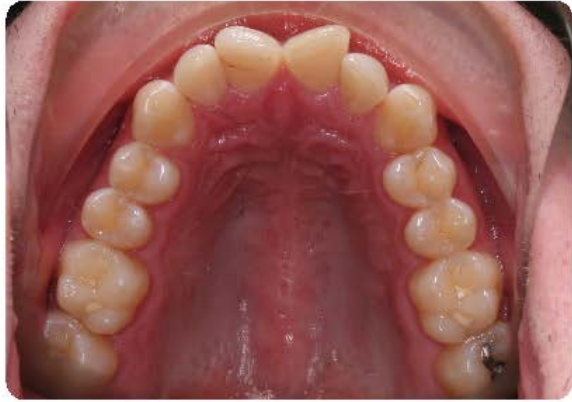Initial

Final

37 year old Male
Class II malocclusion and tooth #7 in crossbite and crowding treated with Invisalign®. Distalized right and left upper teeth to Class I.
Treatment Length: 22 months



Treated by Dr. Bella Shen Garnett



Initial

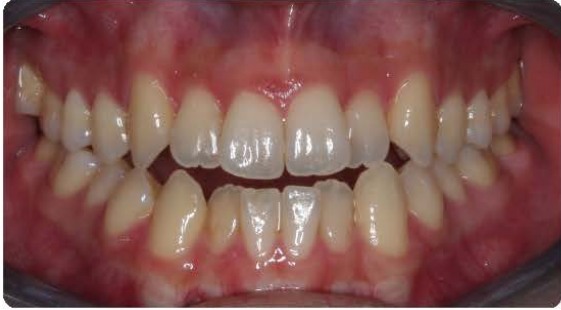Final

25 year old Male
Crowding and anterior crossbite treated with Invisalign®
Treatment Length: 24 months

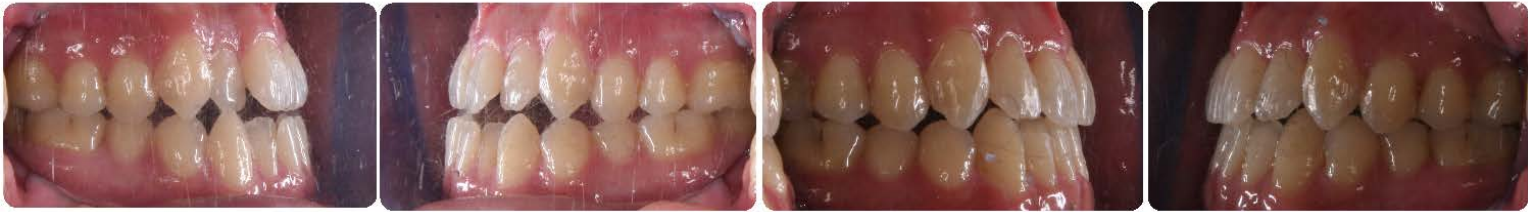
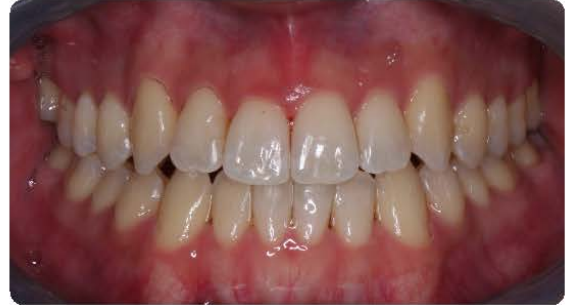
Treated by Dr. Bella Shen Garnett

Initial



Final

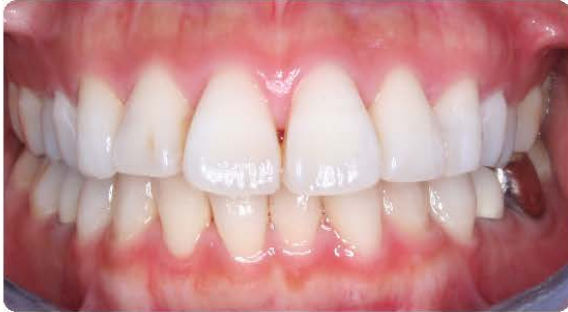

25 year old Male
Class III Openbite and Crowding treated with Invisalign® and Class III elastics
No Surgery
Treatment Length: 16 months

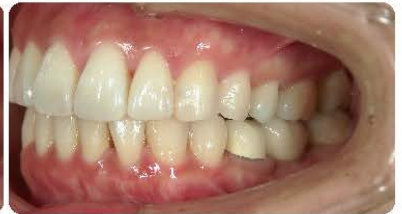
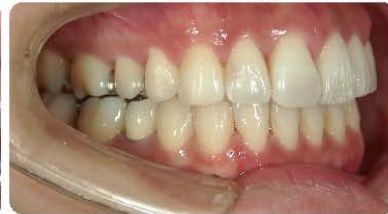
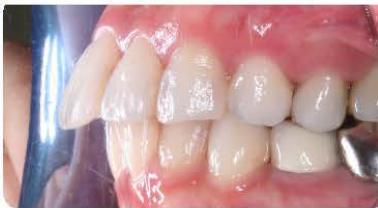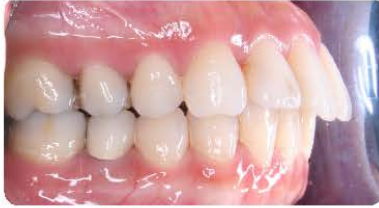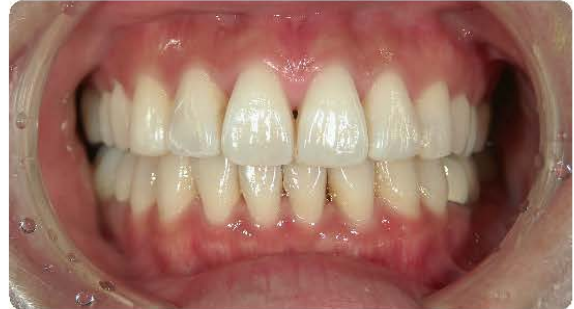Treated by Dr. Bella Shen Garnett

Initial



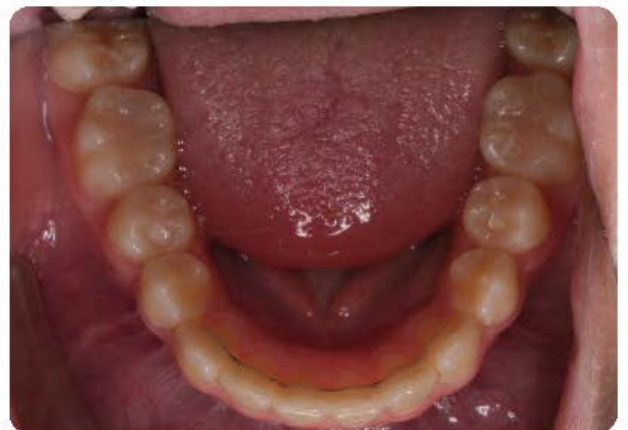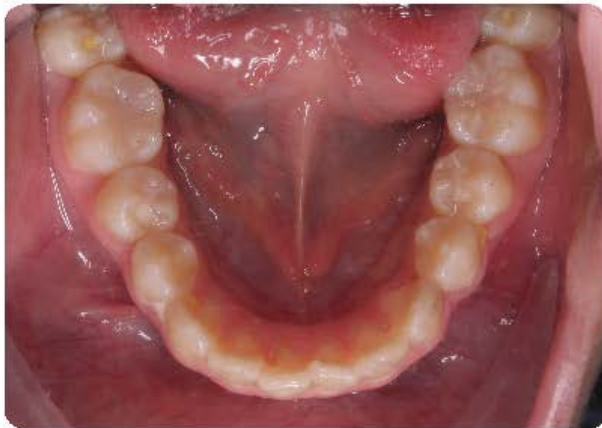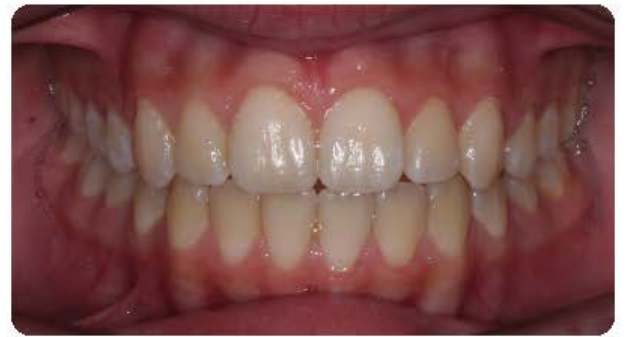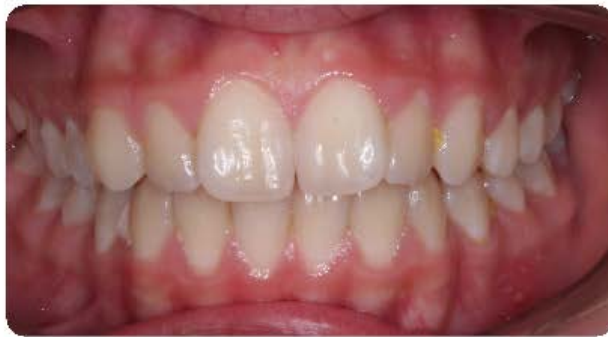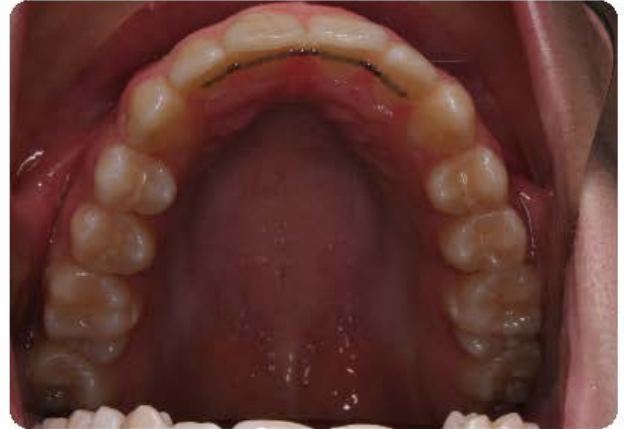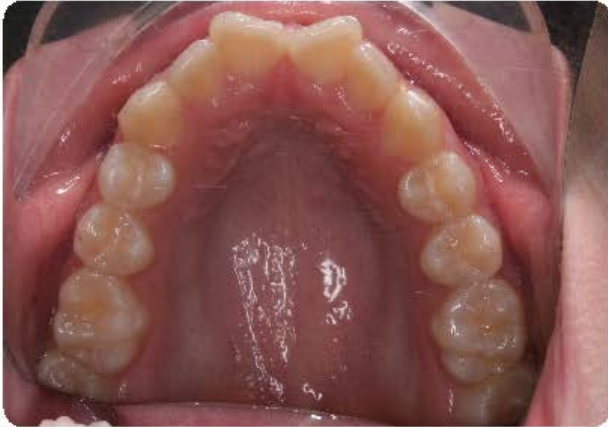Final



25 year old Female
Protrusion treated with Invisalign®
Treatment Length: 15 months



Treated by Dr. Bella Shen Garnett



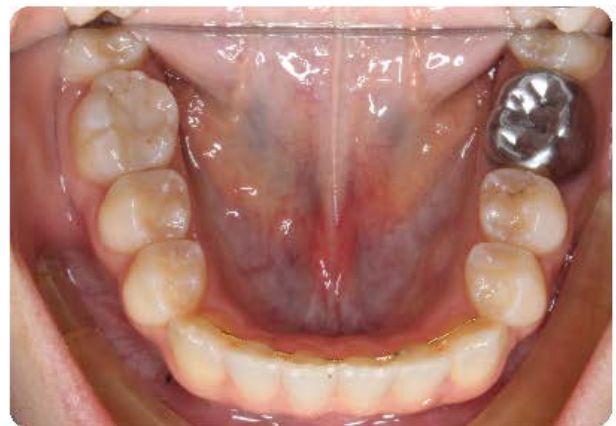
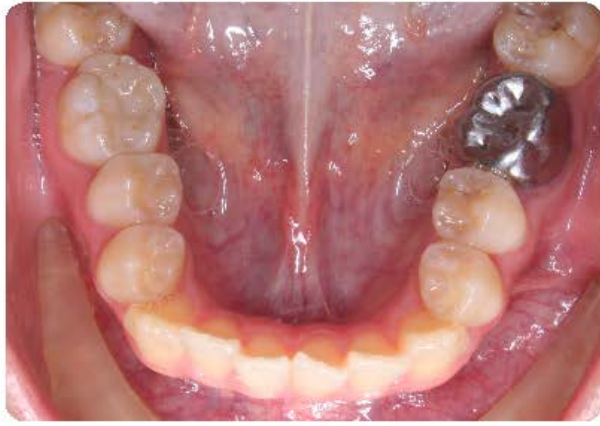
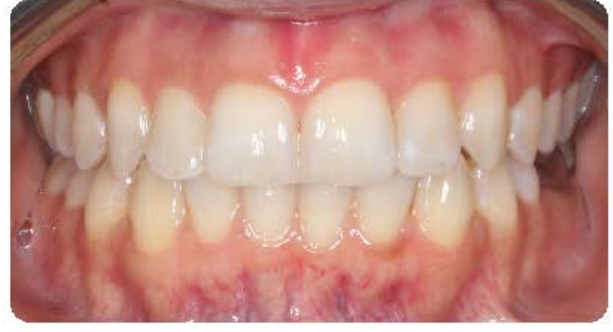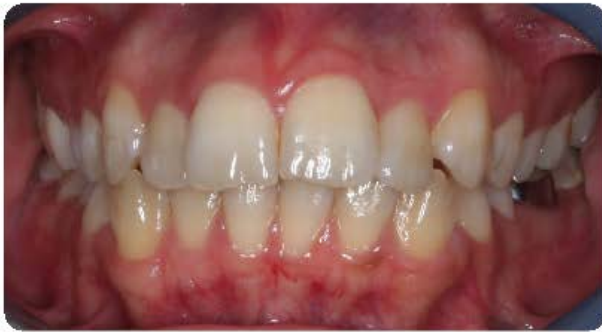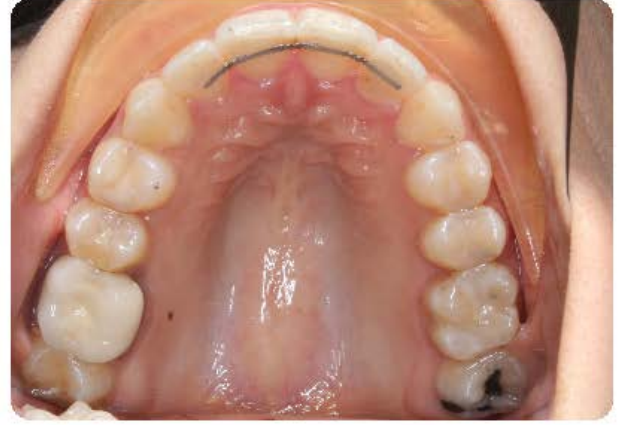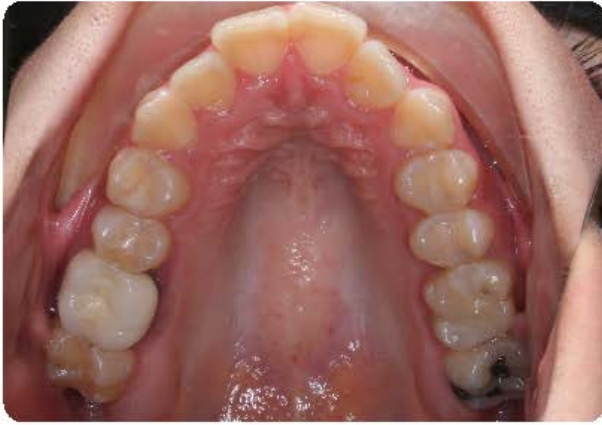Initial

Final

13 year old Female
Overbite and Crowding treated with Invisalign® Teen
Treatment Length: 14 months



Treated by Dr. Bella Shen Garnett



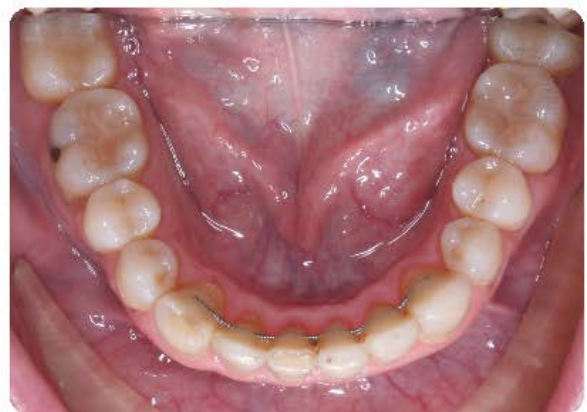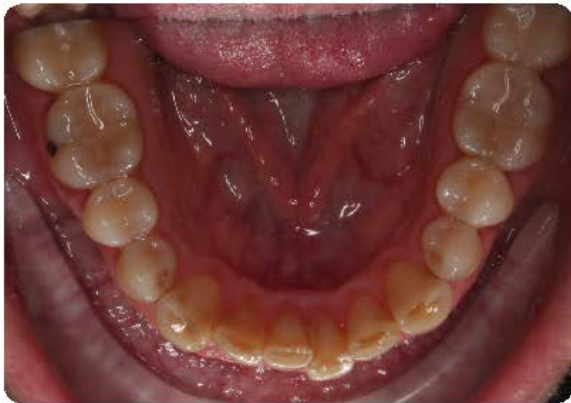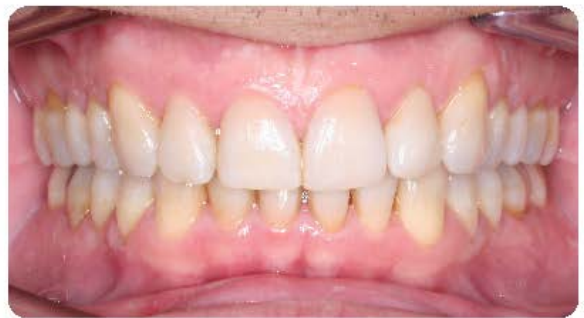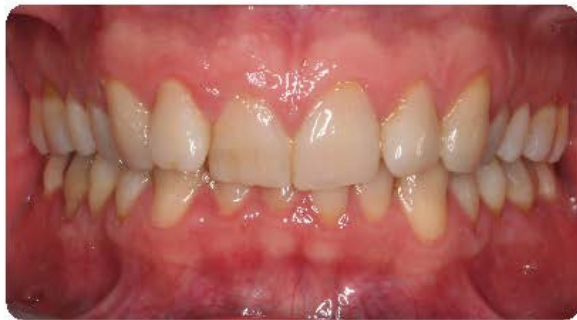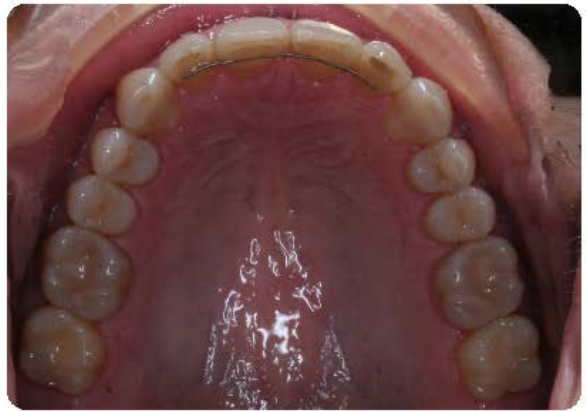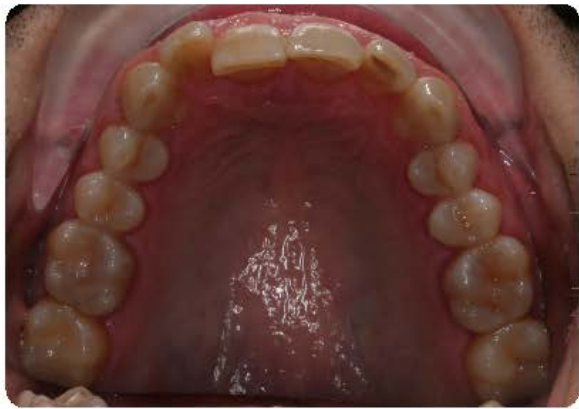Initial

Final

31 year old Female
Overjet and Crowding treated with Invisalign®
Treatment Length: 24 months



Treated by Dr. Bella Shen Garnett



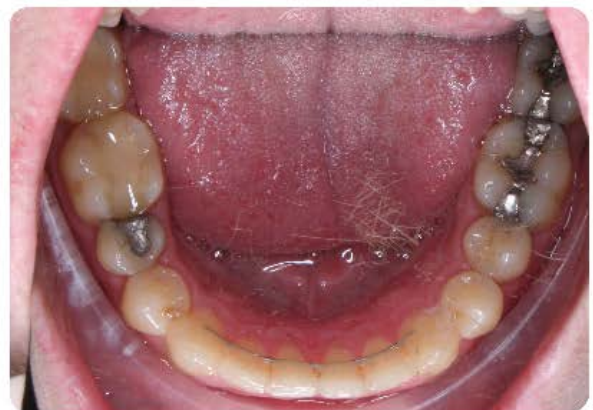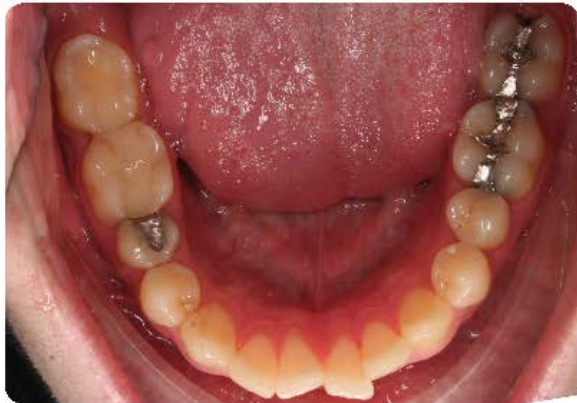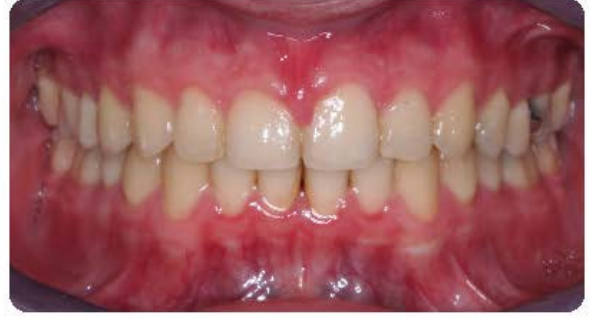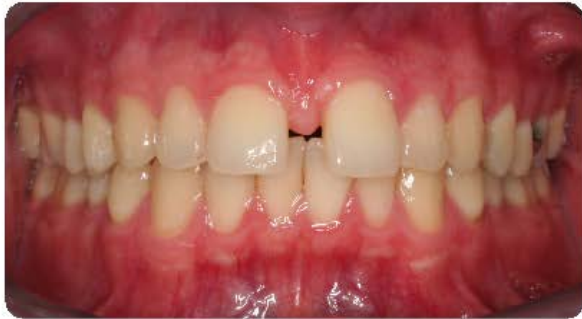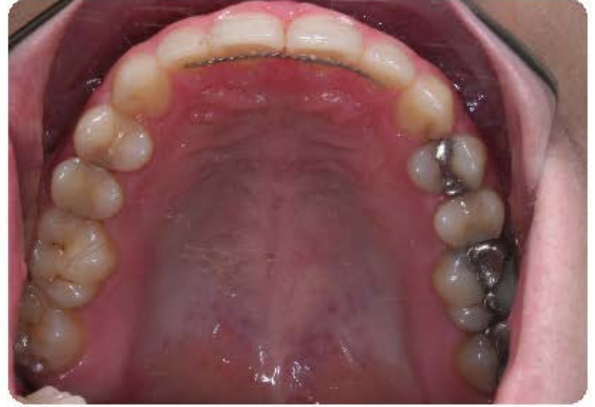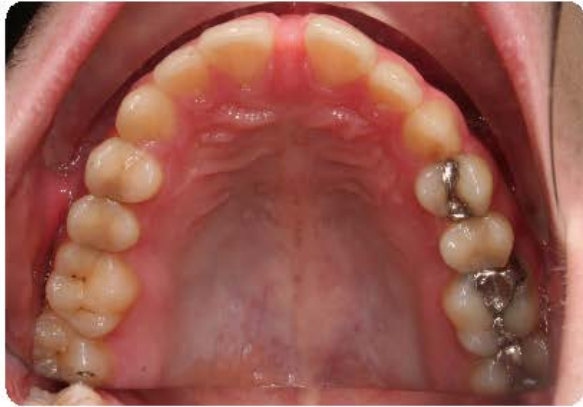Initial

Final

35 year old Male
Deep Bite treated and anterior crowding treated with Invisalign®. We distalized the upper teeth to correct to Class I and create space to resolve crowding.
Treatment Length: 10 months



Treated by Dr. Bella Shen Garnett



Initial

Final

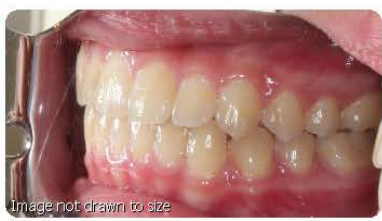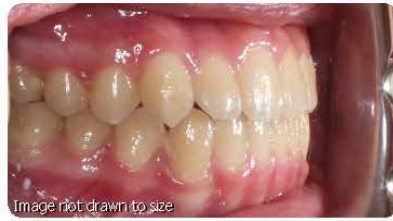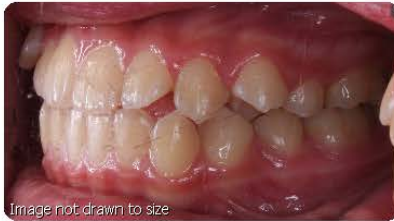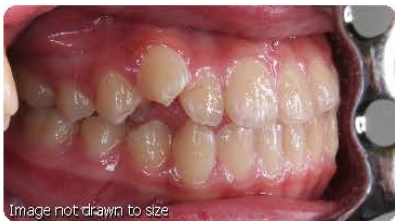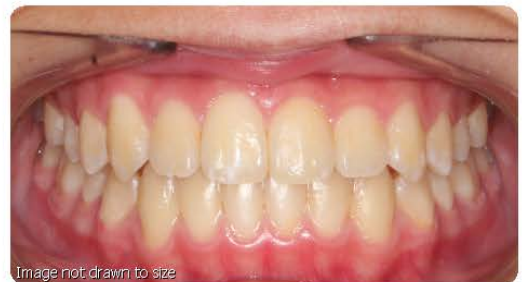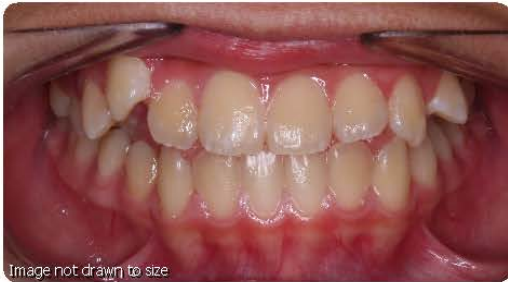26 year old Male
Lower crowding and upper spacing and deep overbite treated with Invisalign®
Treatment Length: 18 months



Treated by Dr. Bella Shen Garnett

Initial

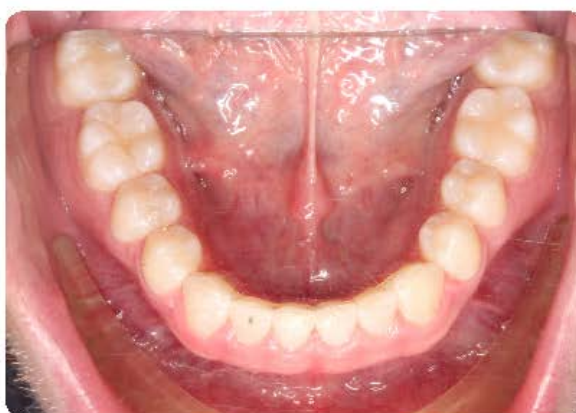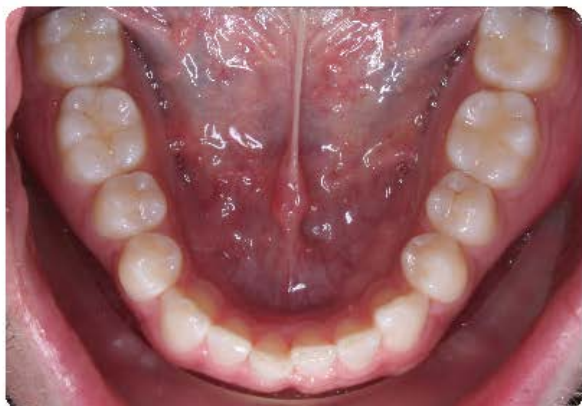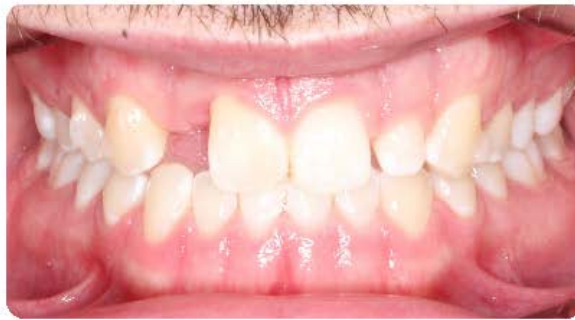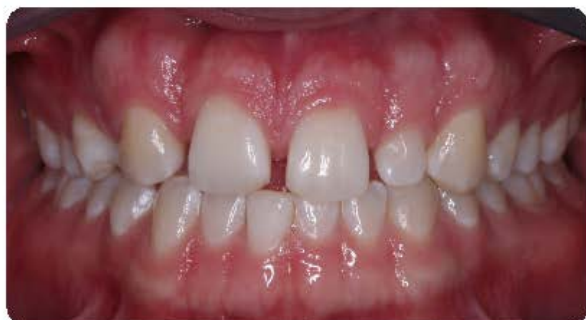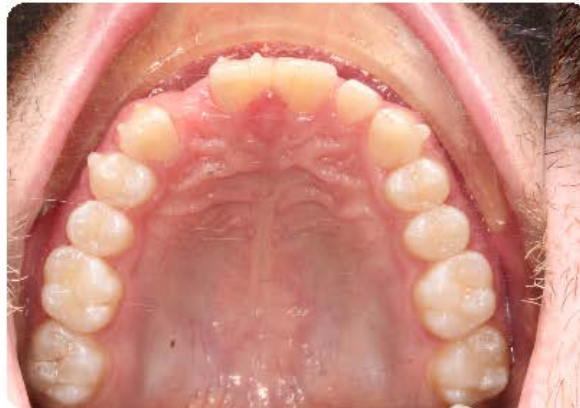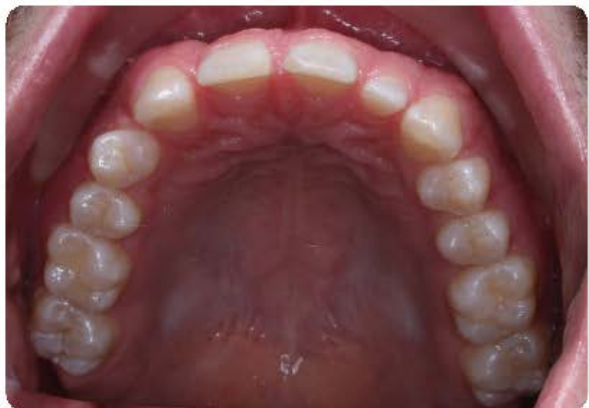Final



12 year old Female
Crowding and Spacing treated with Invisalign® Teen
Treatment Length: 18 months



Treated by Dr. Bella Shen Garnett



Initial

Final

23 year old Male

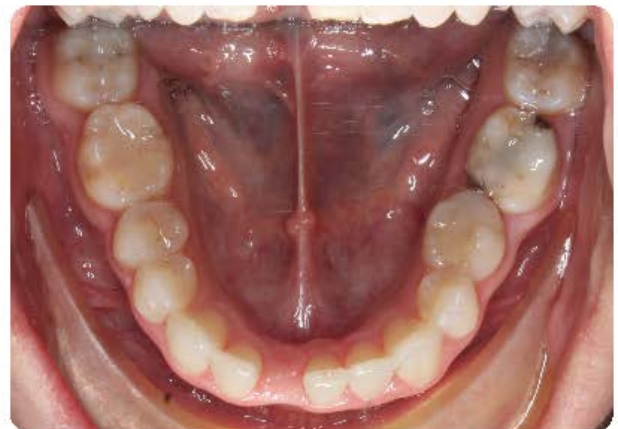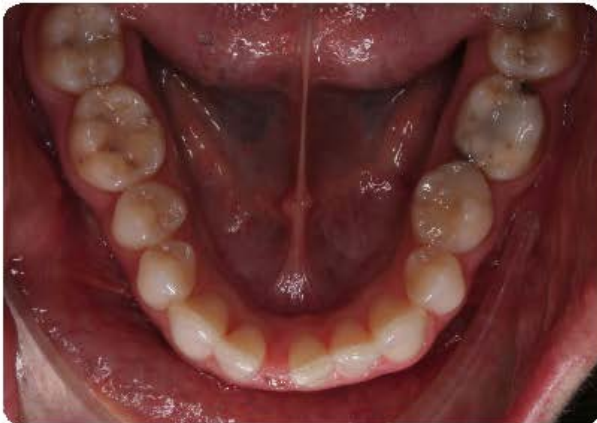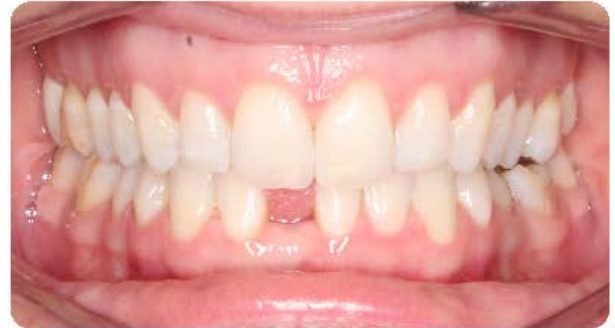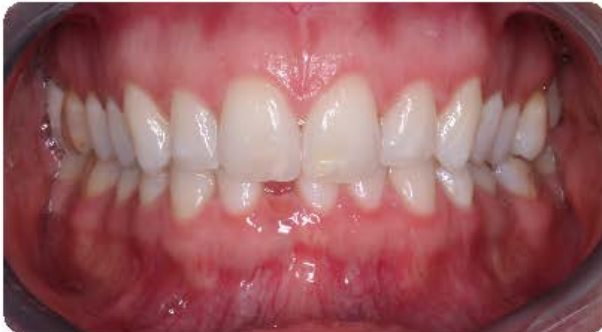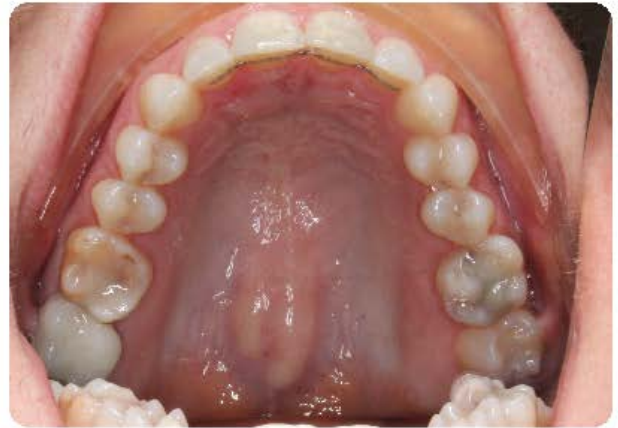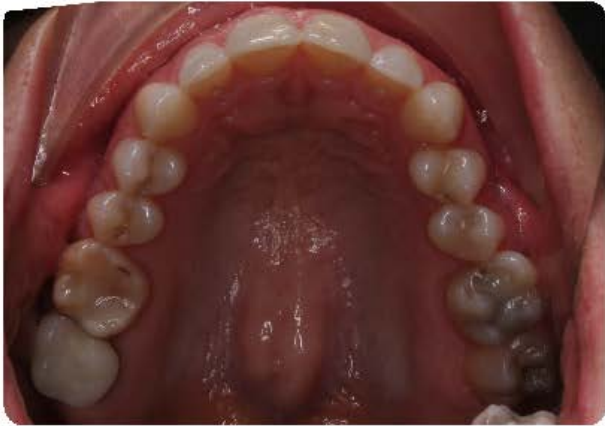Missing tooth #7 and tooth #10 is a peg lateral. Opened space for implant to replace #7 and kept roots upright and opened space for future veneer on #10.

Treated with Invisalign® only.

Treatment Length: 18 months



Treated by Dr. Bella Shen Garnett



Initial

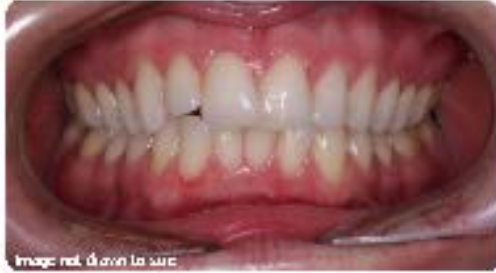Final

32 year old Female
Missing a lower incisor and needed room for implant. Severe Overbite. Treated
with Invisalign® and opened space for implant
Treatment Length: 19 months

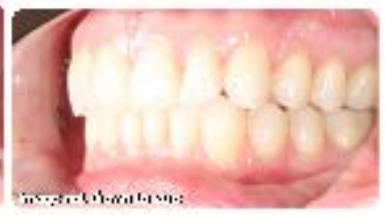
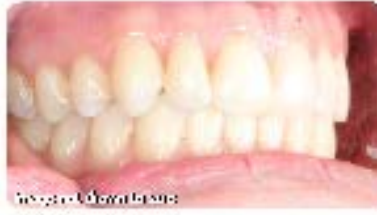
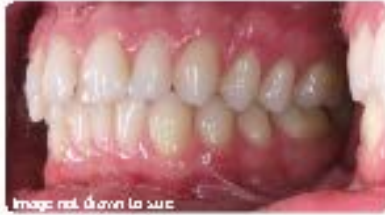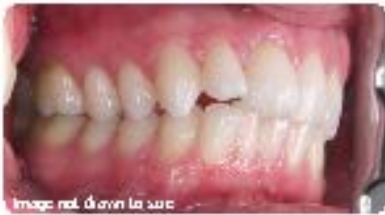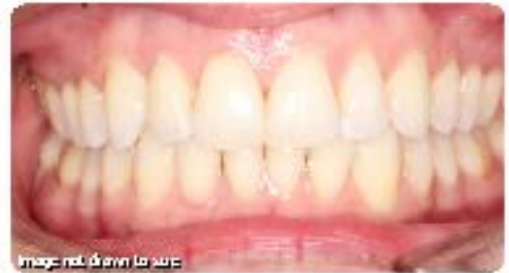Treated by Dr. Bella Shen Garnett

Initial



Final



31 year old Male

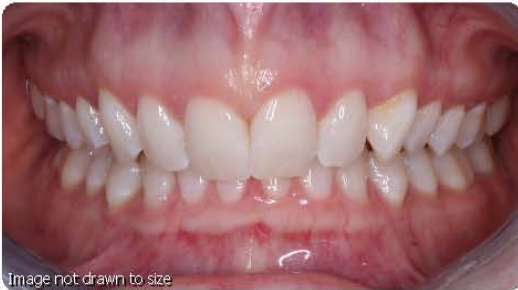Class II and presents with anterior crowding. Distalized teeth to create space and was treated with Invisalign® and Class II elastics

Treatment Length: 24 months

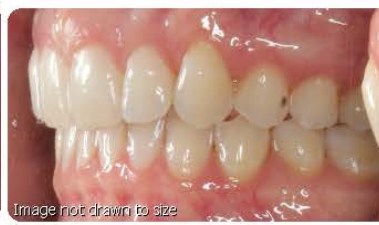
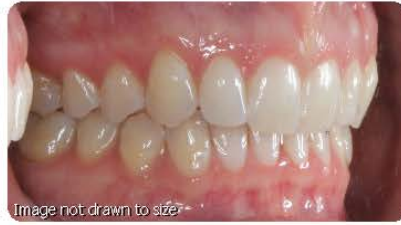
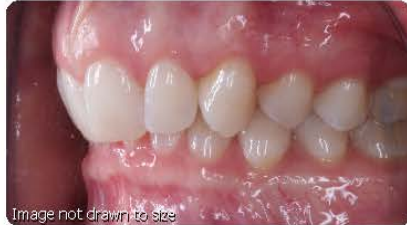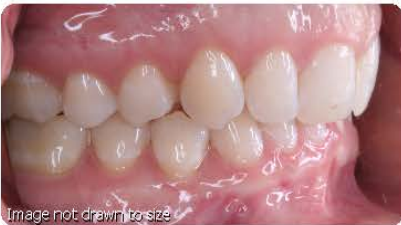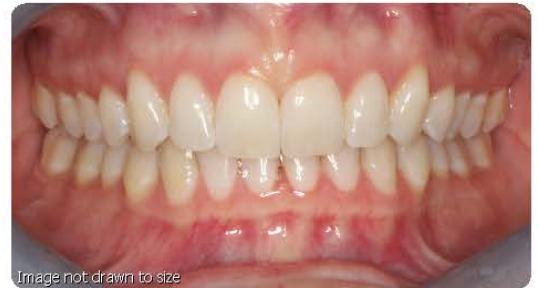Treated by Dr. Bella Shen Garnett

Initial



Final



24 year old Female

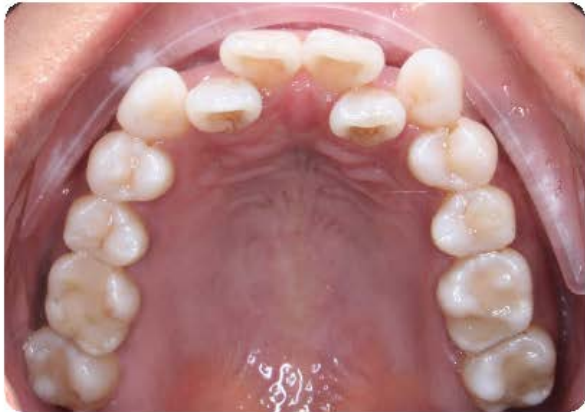Severe Overbite and Crowding. Improved inclination and torque on the upper incisors and opened the bite. Treated by Invisalign®

Treatment Length: 24 months

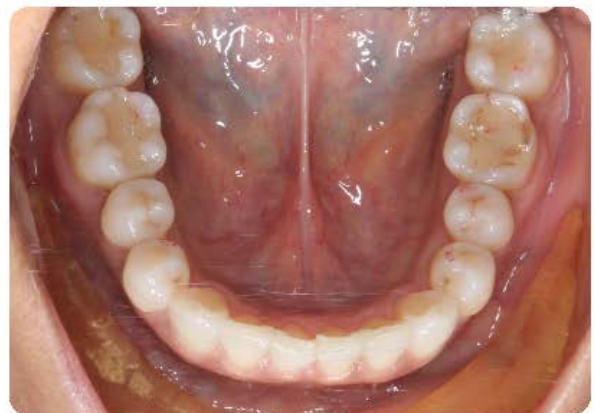
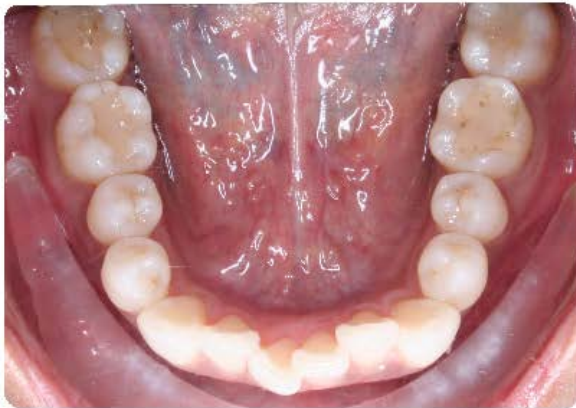
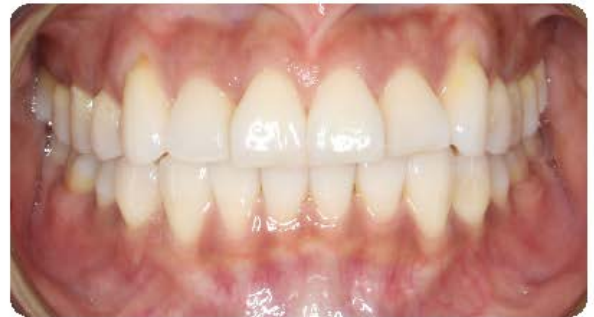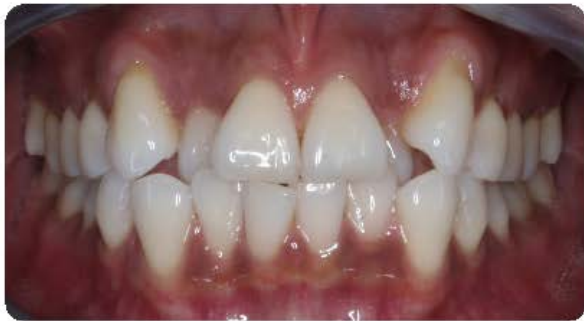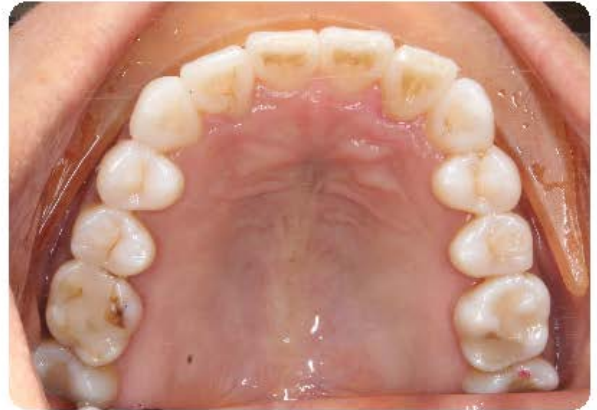Treated by Dr. Bella Shen Garnett

Initial



Final



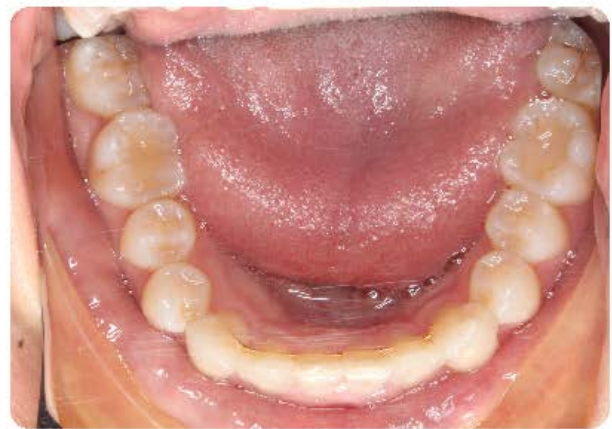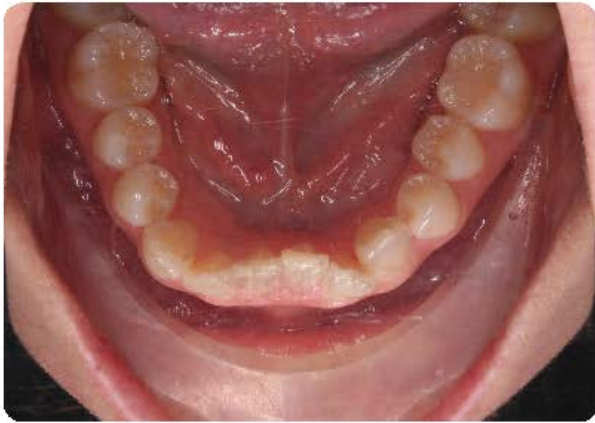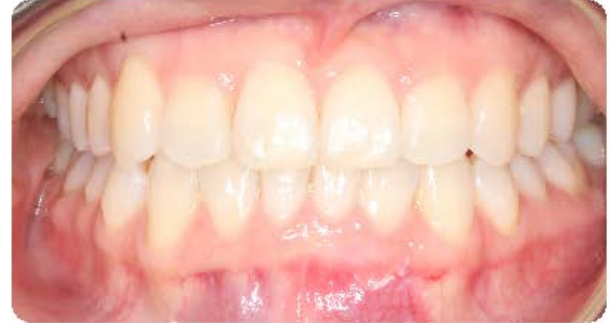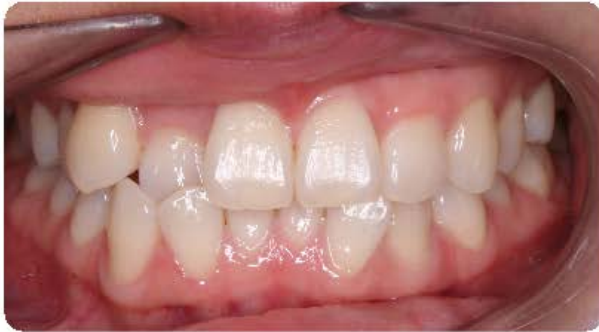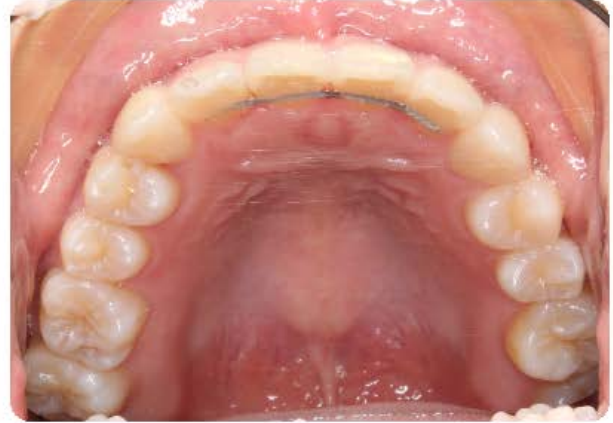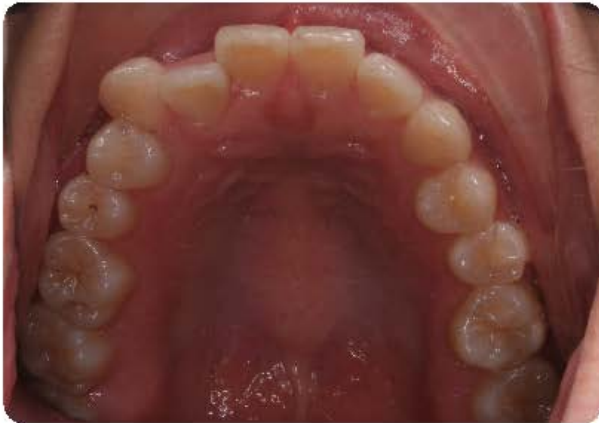32 year old Female
Severe Crowding, midline is shifted to the left, and Crossbite treated with
Invisalign® and IPR
No extractions
Treatment Length: 24 months



Treated by Dr. Bella Shen Garnett

Initial

Final

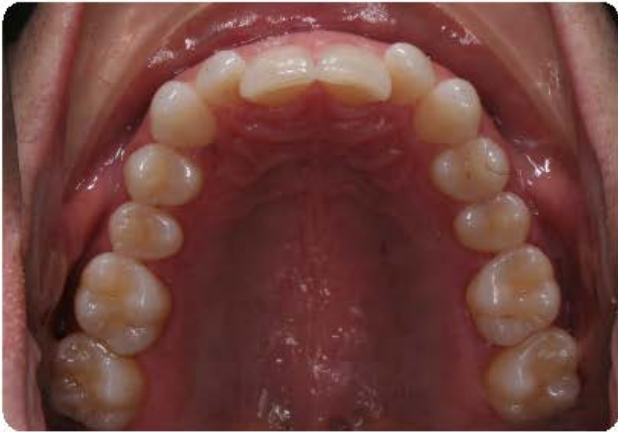

39 year old Female
Moderate Crowding and upper midline is shifted to the left, treated with
Invisalign®
Treatment Length: 20 months

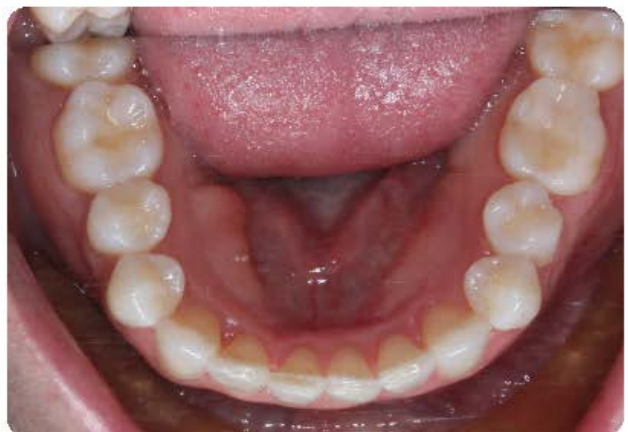
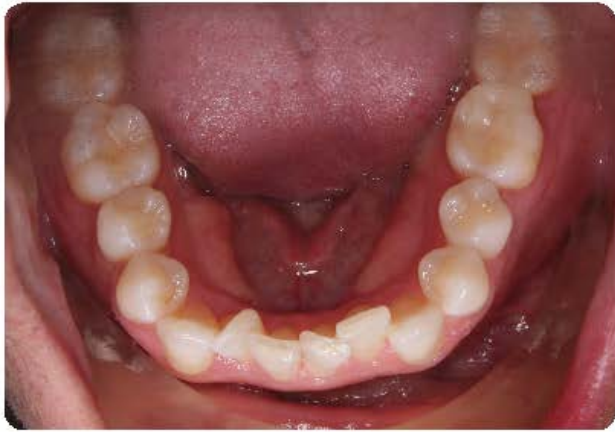
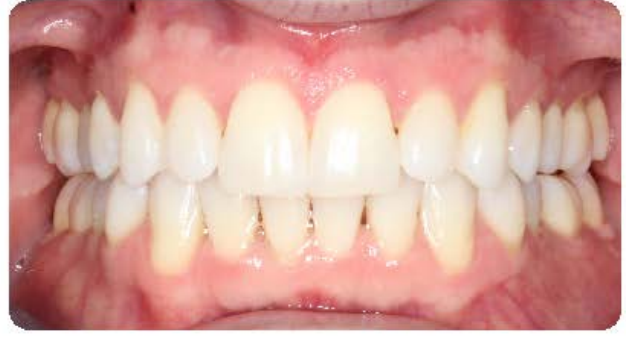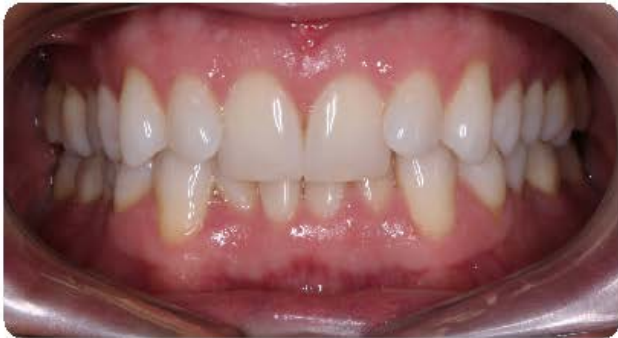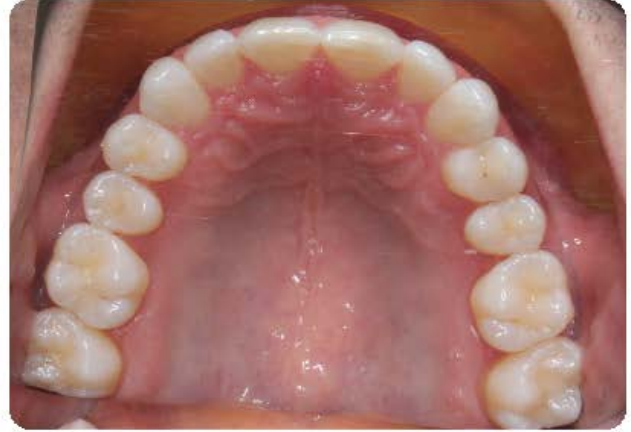Treated by Dr. Bella Shen Garnett

Initial



Final



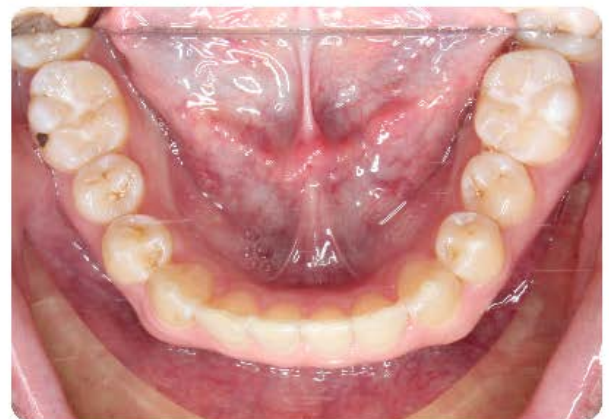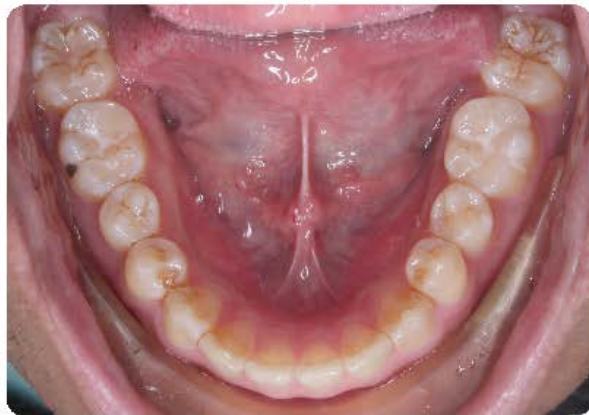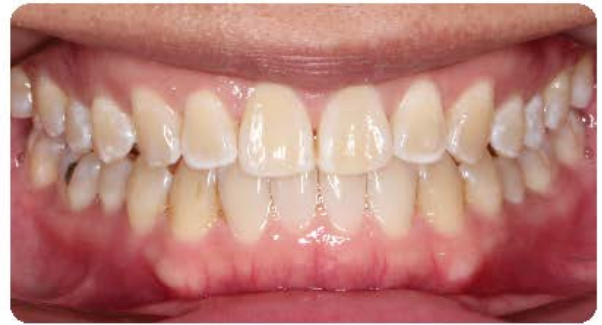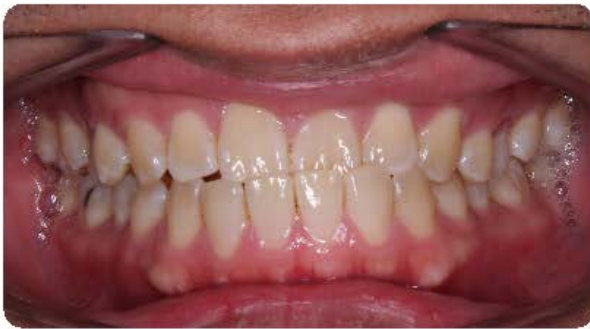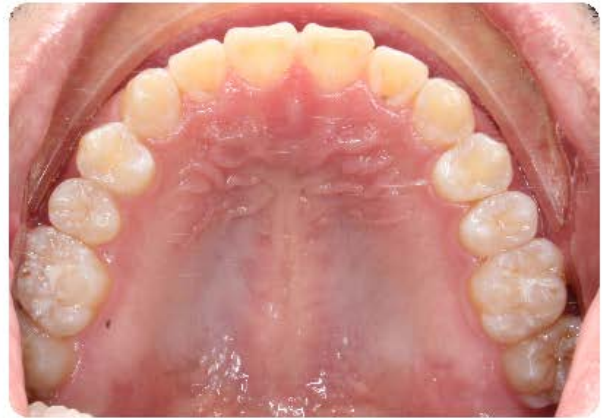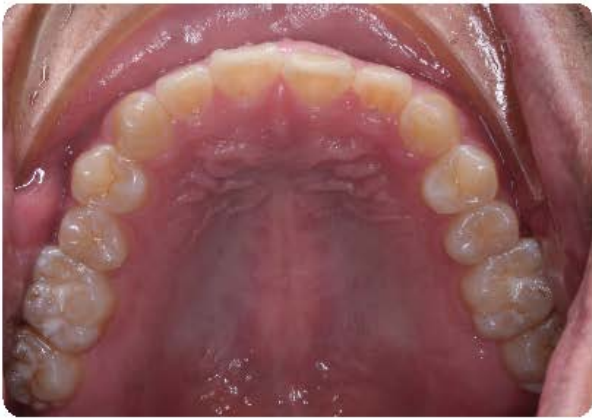39 year old Male
Severe Crowding and deep bite, treated with Invisalign®
Treatment Length 20 months



Treated by Dr. Bella Shen Garnett

Initial

Final



30 year old Male

Underbite with a Crossbite tendency treated with Invisalign® and Class III elastics

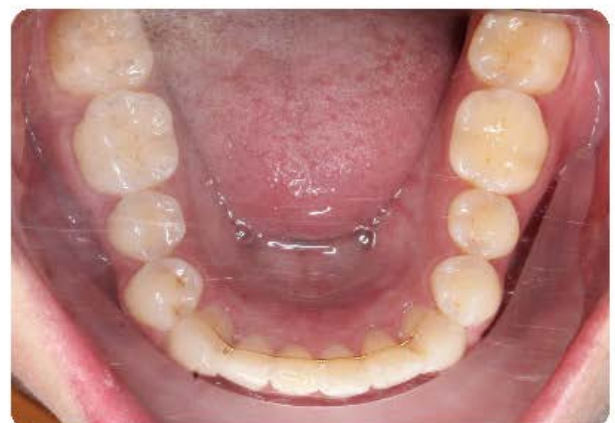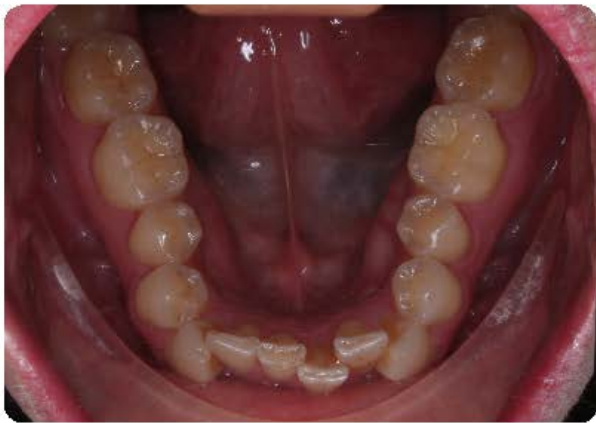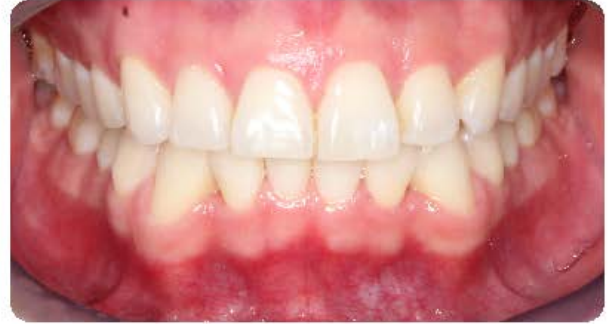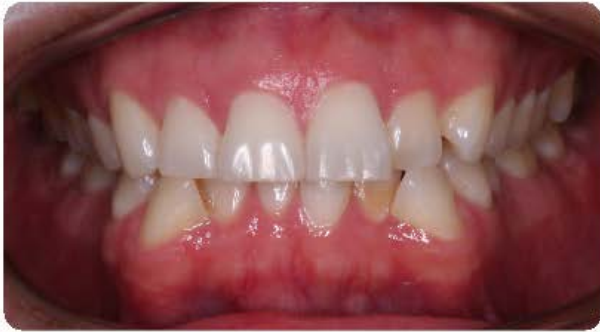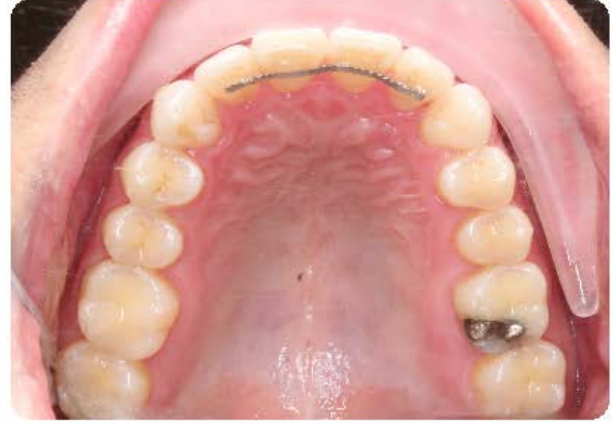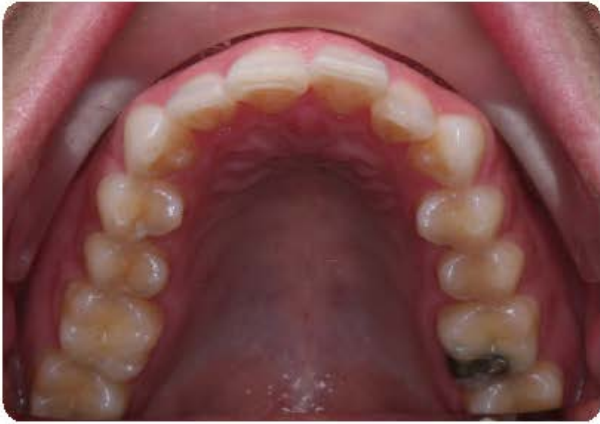Treatment Length: 18 months



Treated by Dr. Bella Shen Garnett

Initial

Final



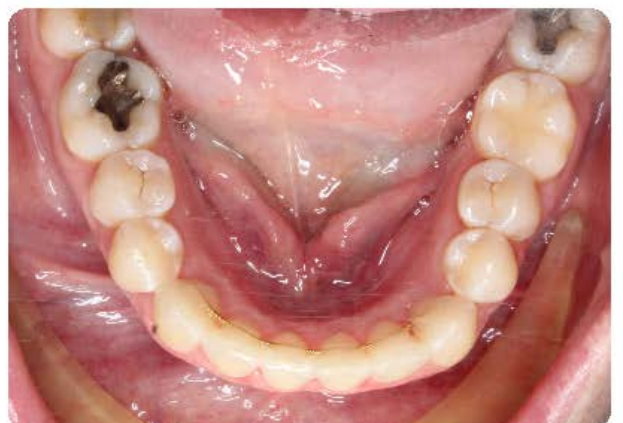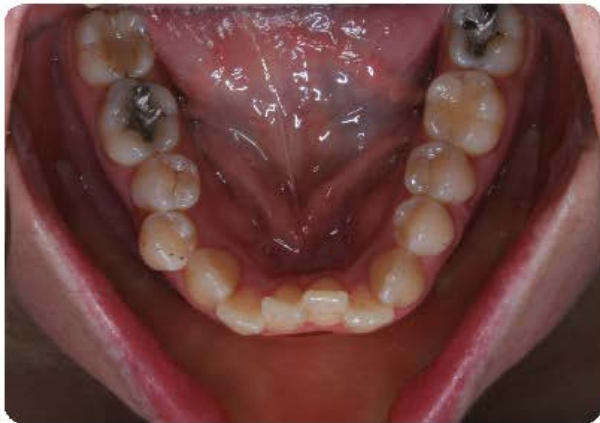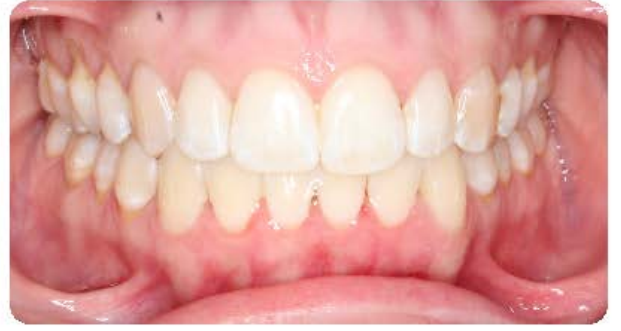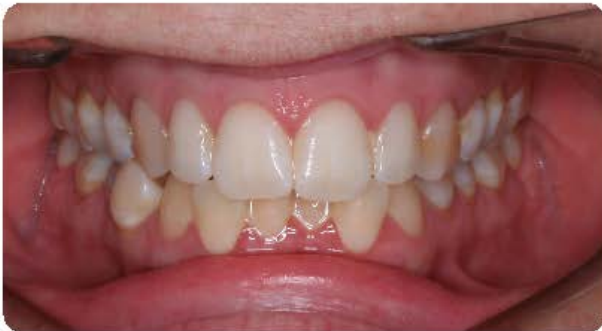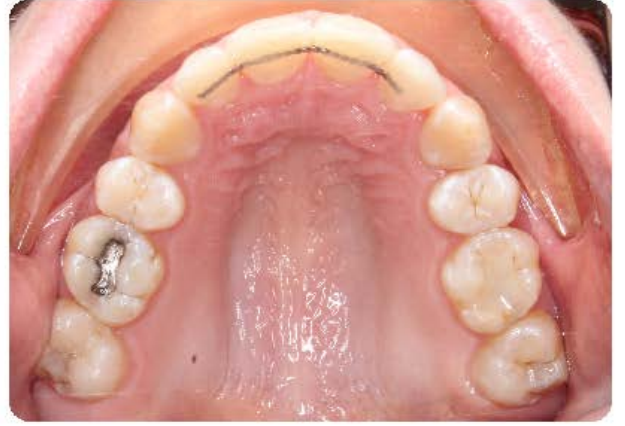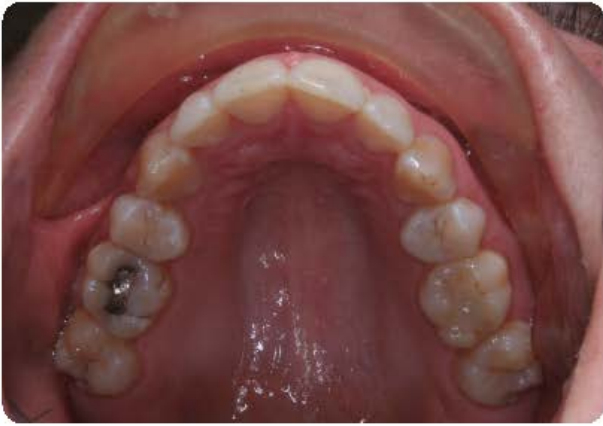30 year old Male
Crowding with a moderate Overbite and partial Crossbite tendency treated by
Invisalign®
Treatment Length: 18 months



Treated by Dr. Bella Shen Garnett

Initial

Final

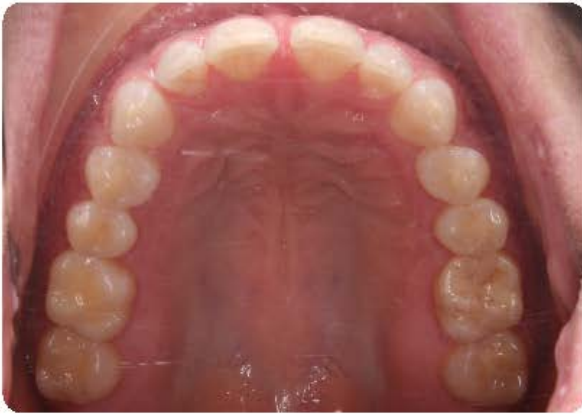

37 year old Female
Severe Crowding and posterior crossbite tooth #28 treated with Invisalign®
Treatment Length: 20 months

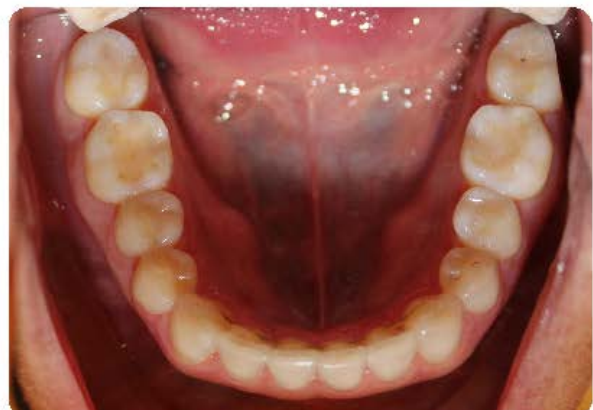
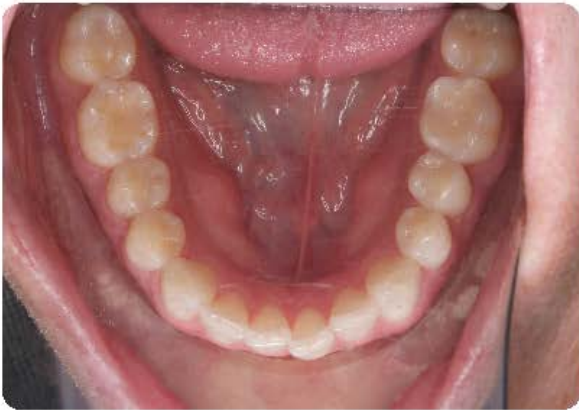
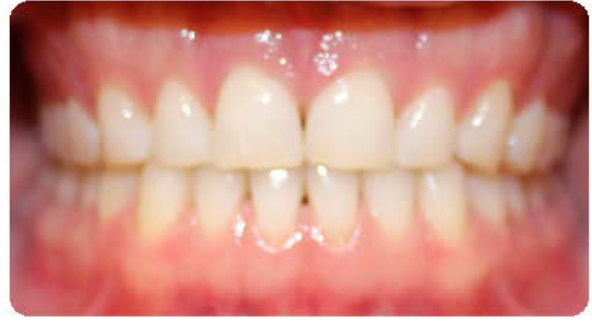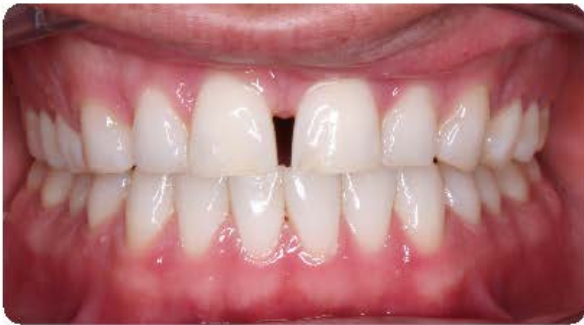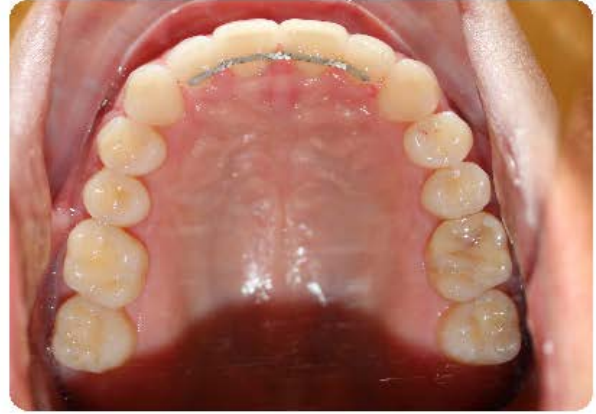Treated by Dr. Bella Shen Garnett

Initial



Final

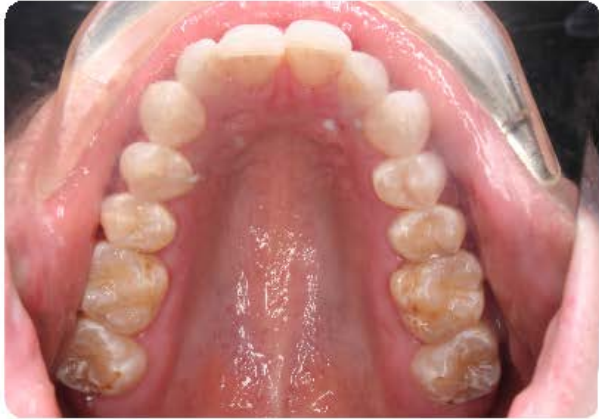

31 year old Male
Edge to Edge Bite and Spacing, treated with Invisalign® and Class III elastics
Treatment Length: 17 months

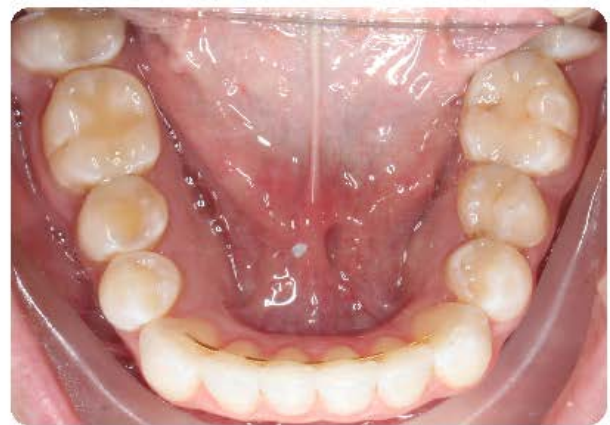
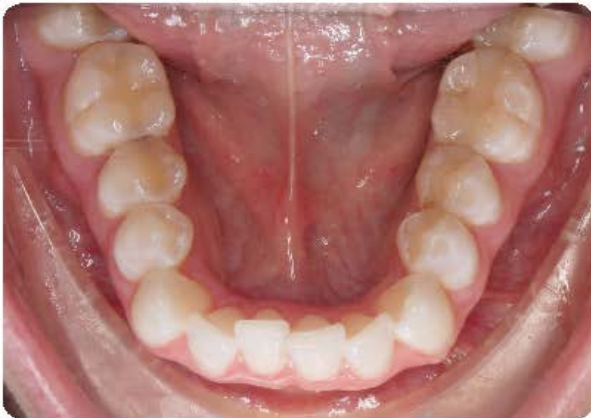
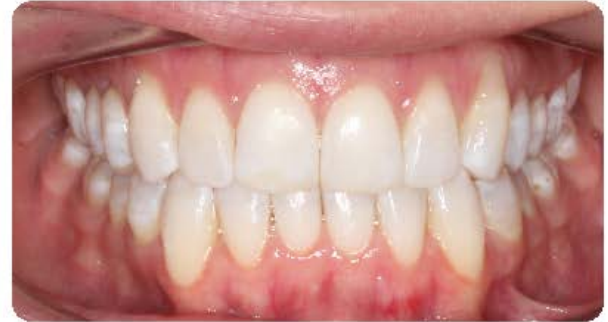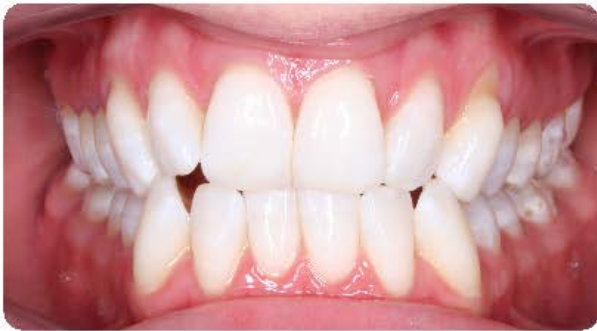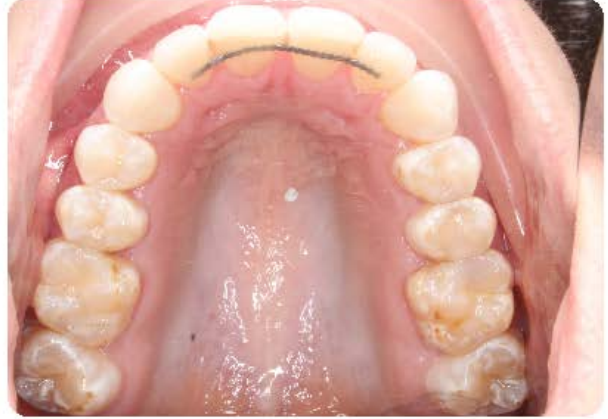Treated by Dr. Bella Shen Garnett

Initial



Final



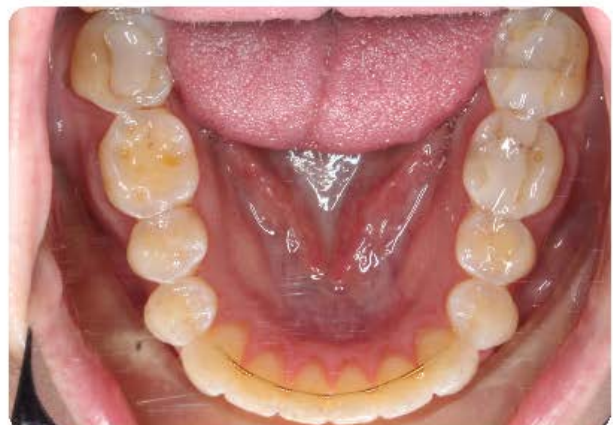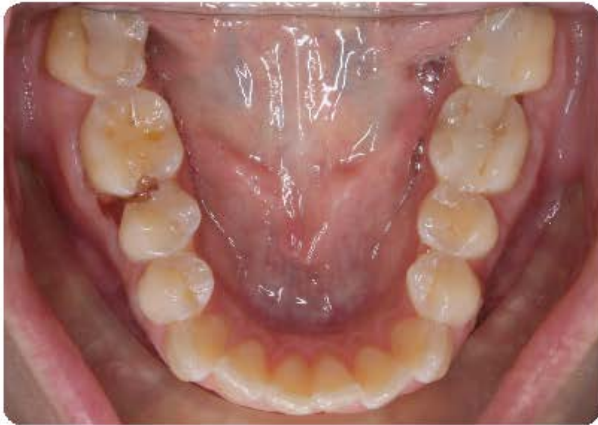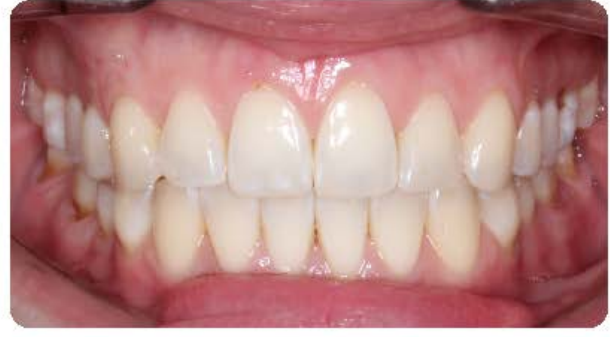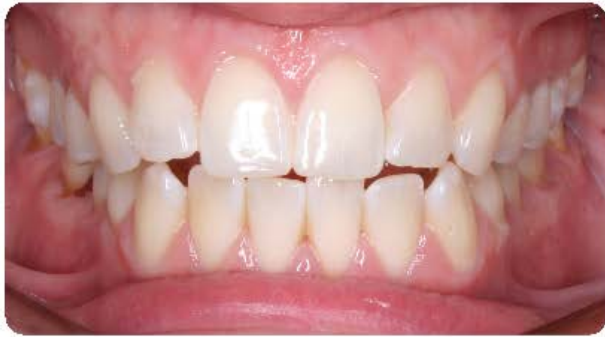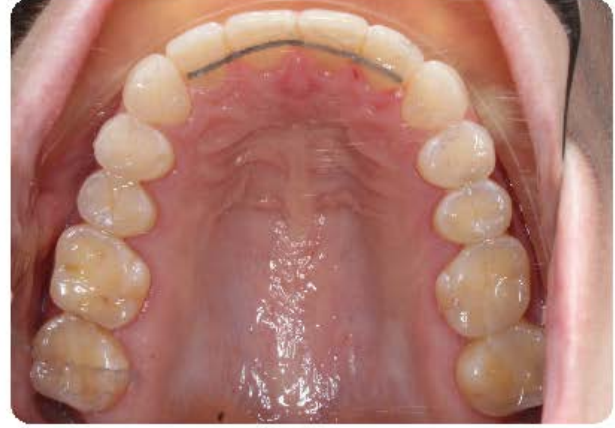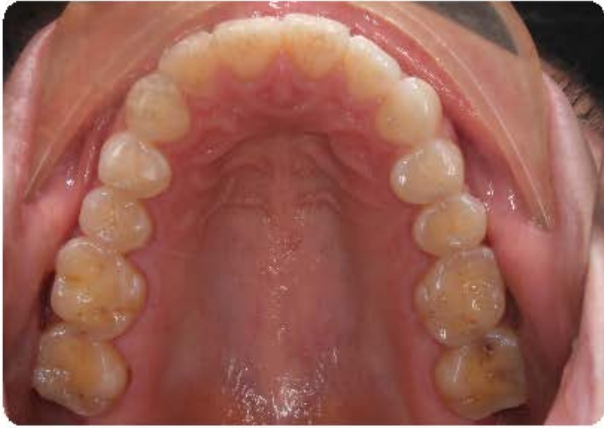Edge to Edge Bite, Recession, and Crowding treated with Invisalign®. Expanded arch forms and closed down bite
31 year old Female
Treatment Length: 13 Months



Treated by Dr. Bella Shen Garnett

Initial

Final

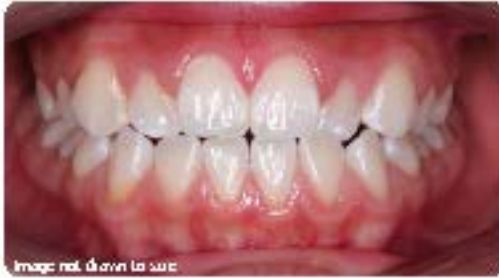

33 year old Female
Open Bite and Edge to Edge Bite with a Tongue Thrust Habit treated with
Invisalign®
Treatment Length: 13 months

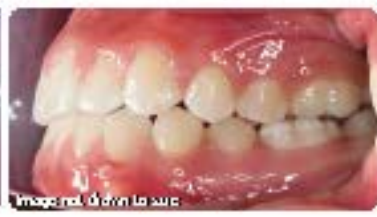
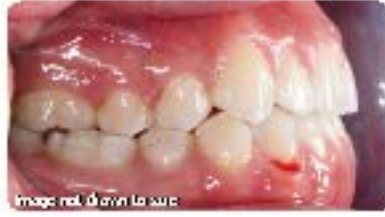
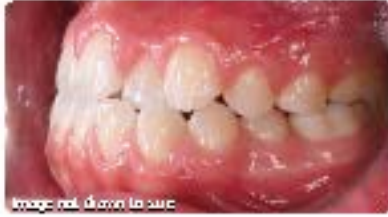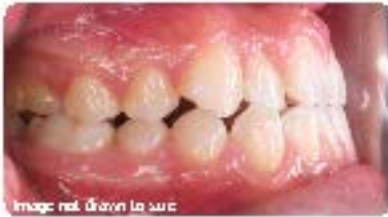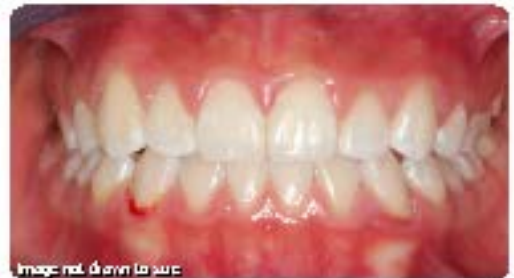Treated by Dr. Bella Shen Garnett

Initial



Final



19 year old Female

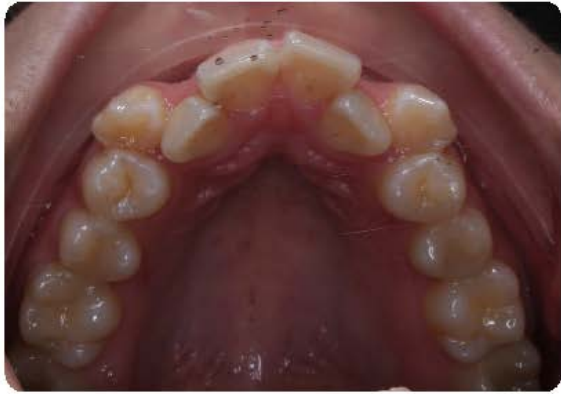Class III, Edge to Edge Bite with a mild tongue thrust, Underbite treated with Invisalign® and Class III elastics

Treatment Length: 16 months

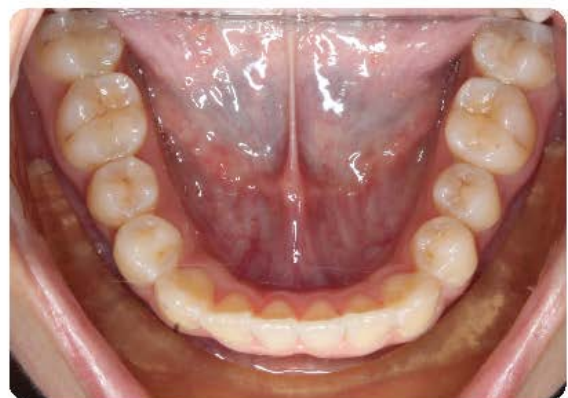
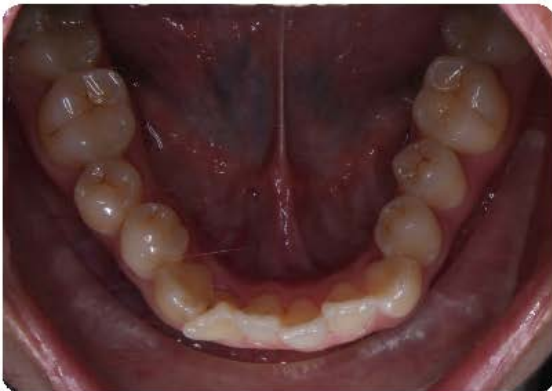
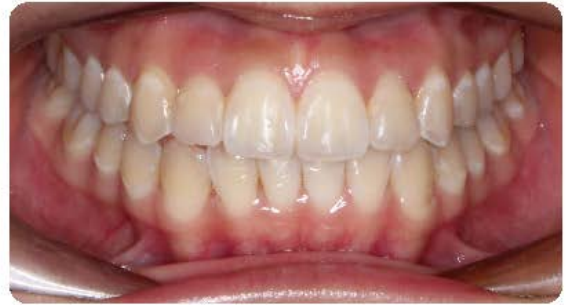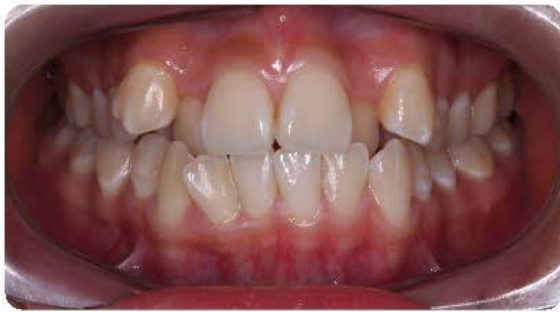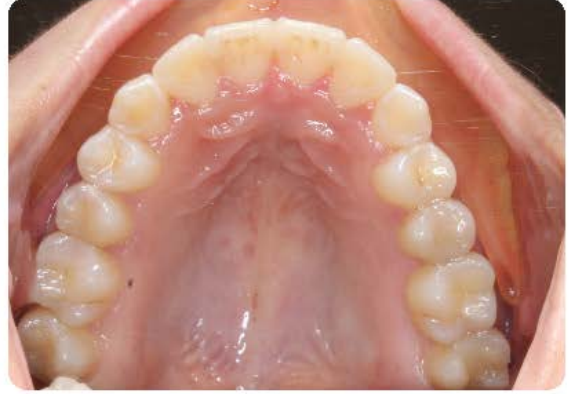Treated by Dr. Bella Shen Garnett

Initial



Final



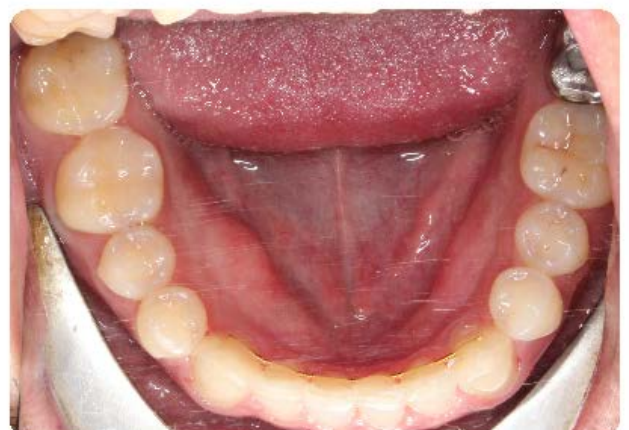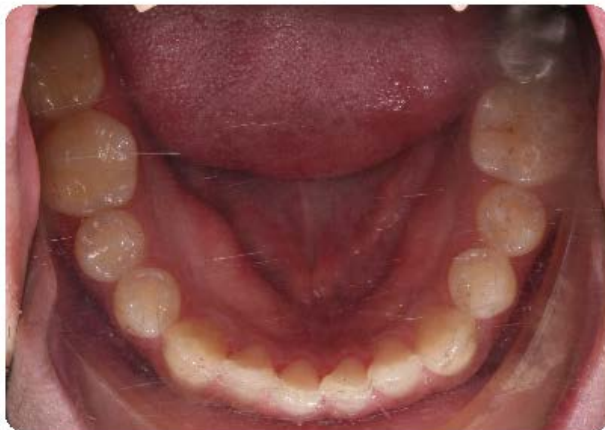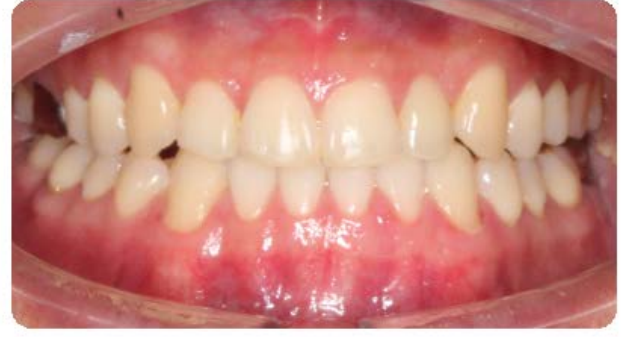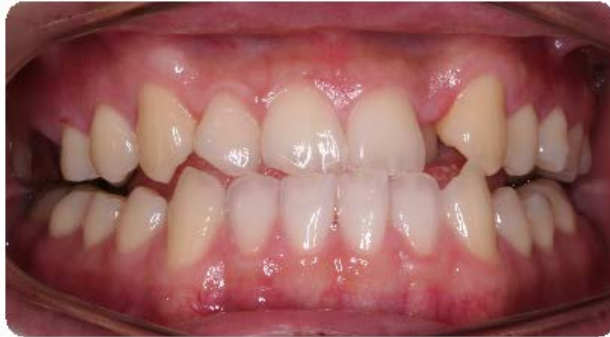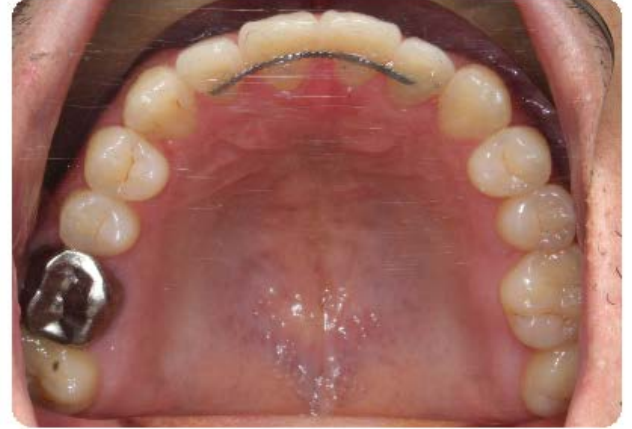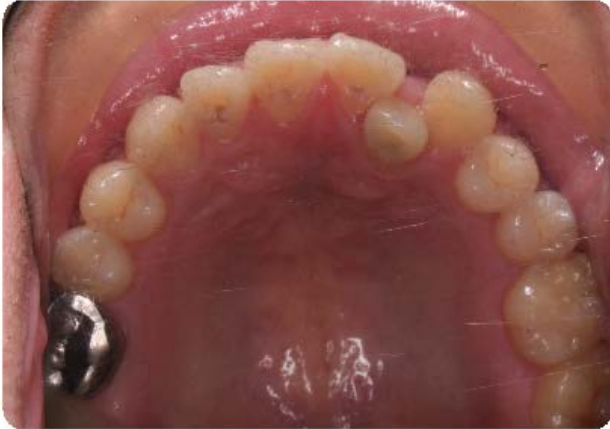20 year old Female
Severe Crowding and Midlines are shifted to the Left, treated with Invisalign®
Treatment Length: 24 Months



Treated by Dr. Bella Shen Garnett

Initial

Final



31 year old male

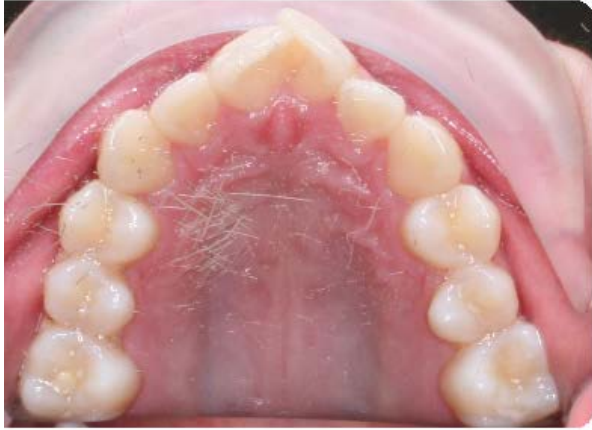Anterior crossbite with a CR/CO shift. He can bite forward edge to edge. Severe Crowding, treated with Invisalign® and Class III elastics

Treatment Length: 18 Months

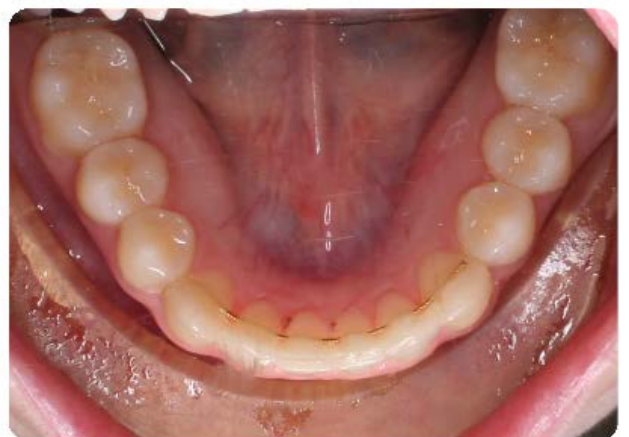
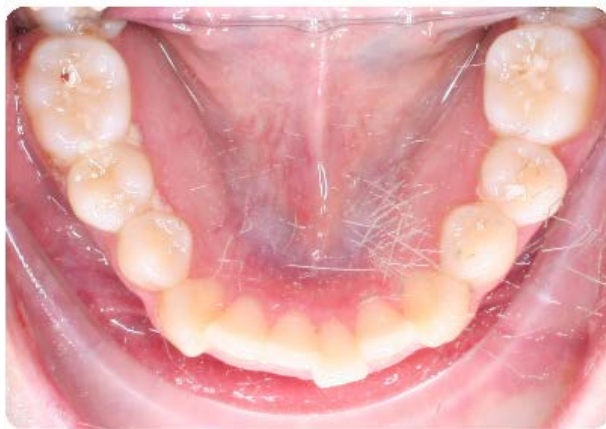
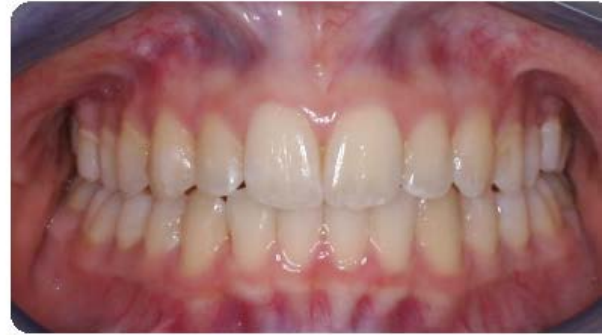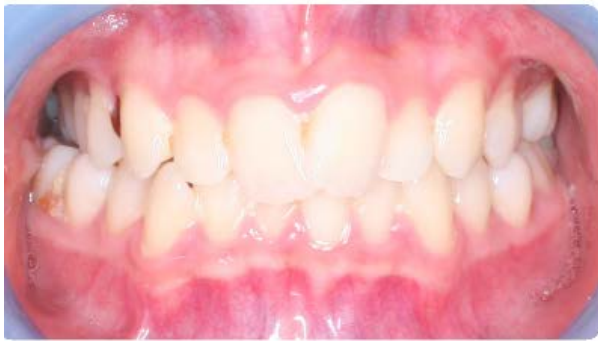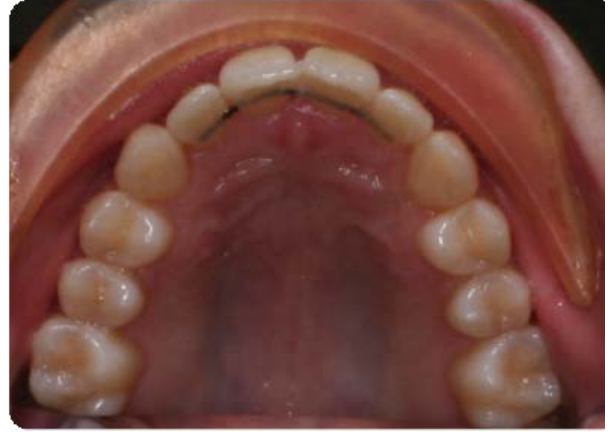Treated by Dr. Bella Shen Garnett

Initial



Final

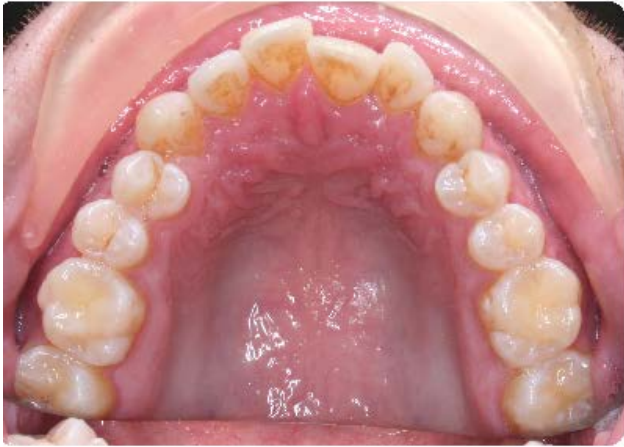

17 year old Female
Crowding, Crossbite, and Overbite treated with Invisalign®
Treatment Length: 18 months

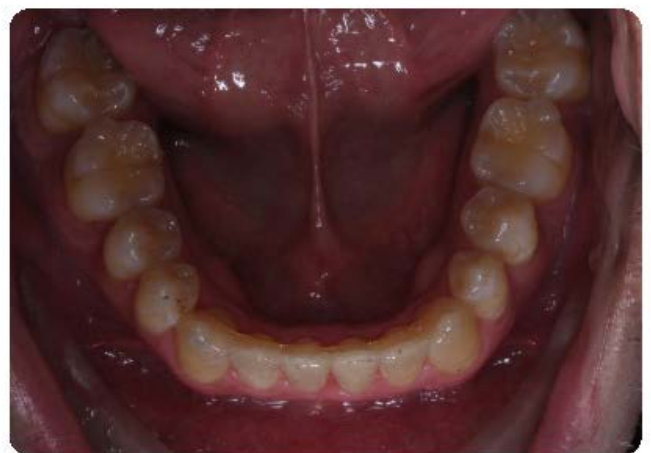
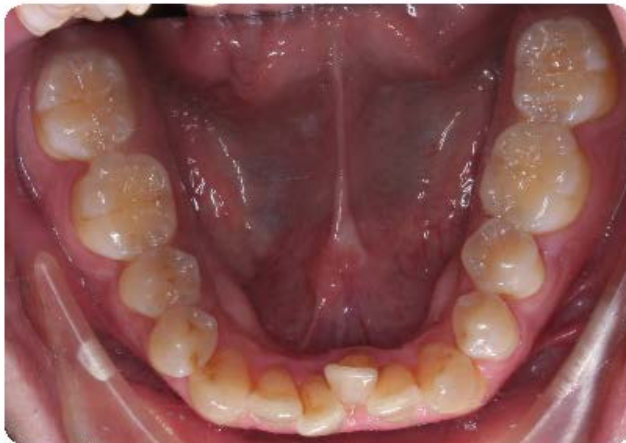
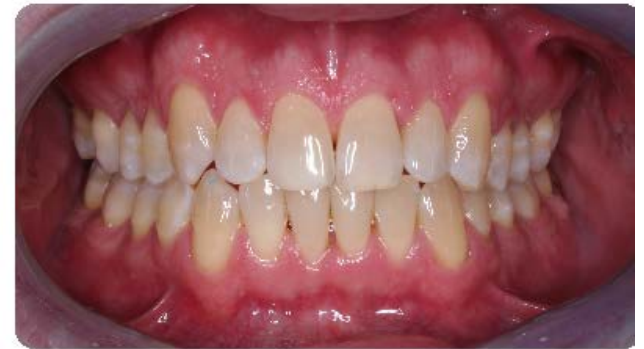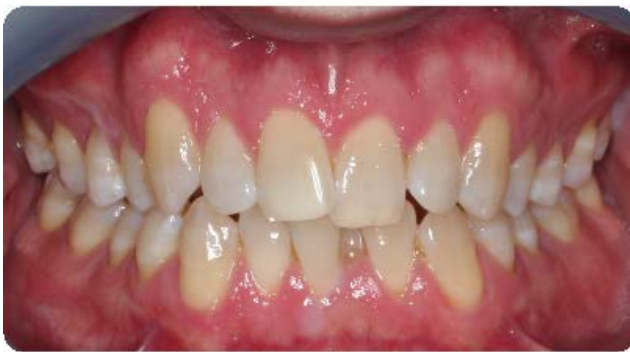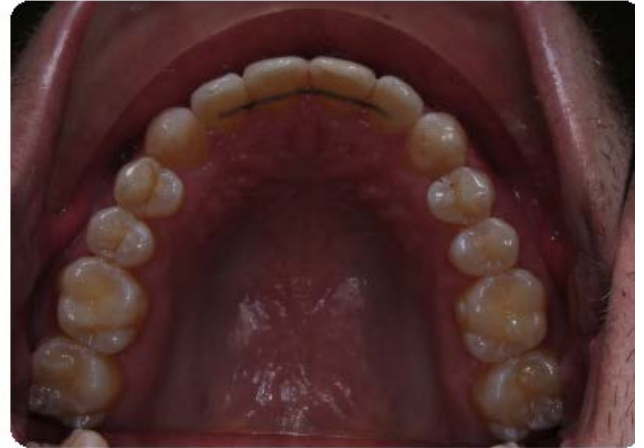Treated by Dr. Bella Shen Garnett

Initial



Final

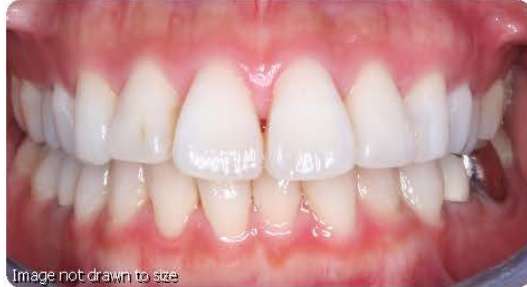

31 year old Male
Severe Crowding treated with Invisalign®
Treatment Length: 13 months

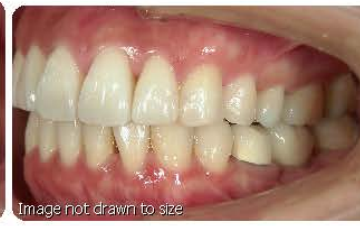
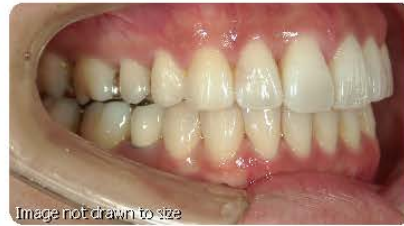
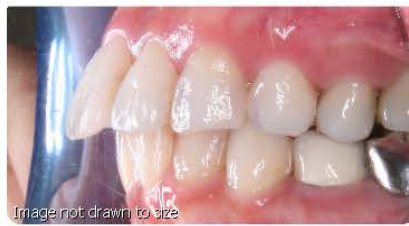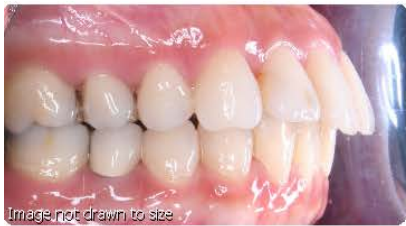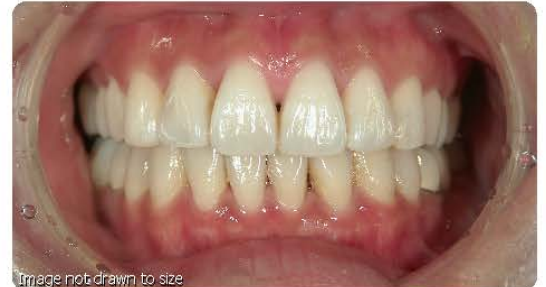Treated by Dr. Bella Shen Garnett

Initial



Final

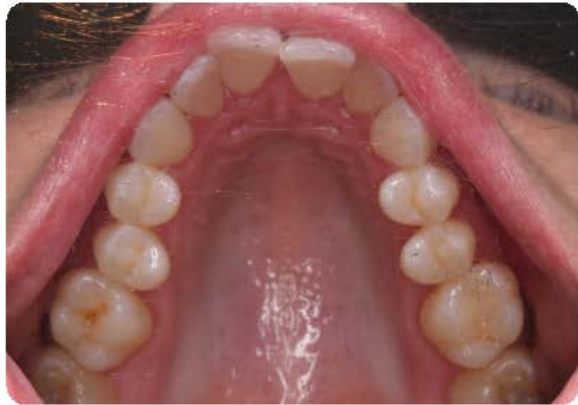

Protrusion treated with Invisalign®
25 year old Female
Treatment Length: 13 months

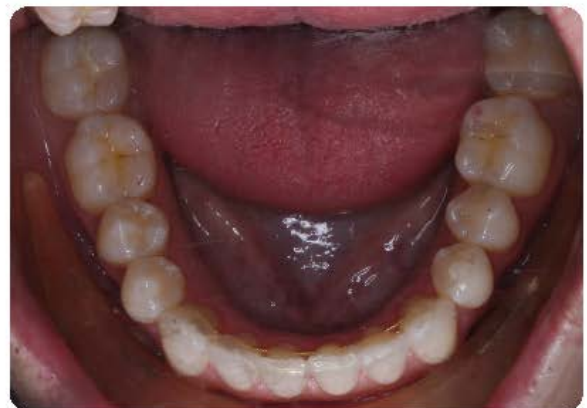
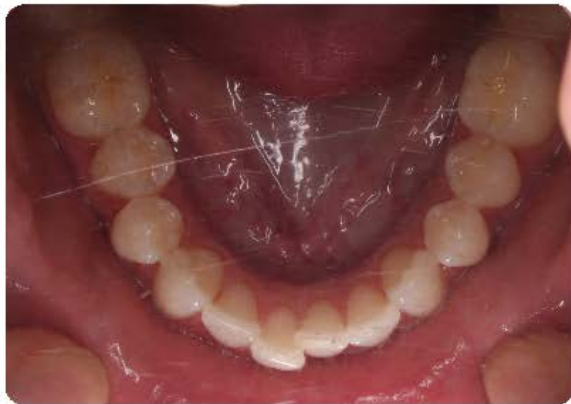
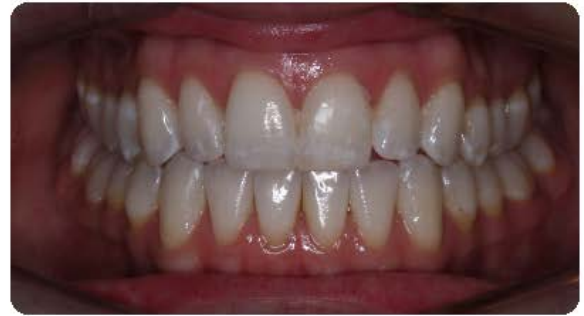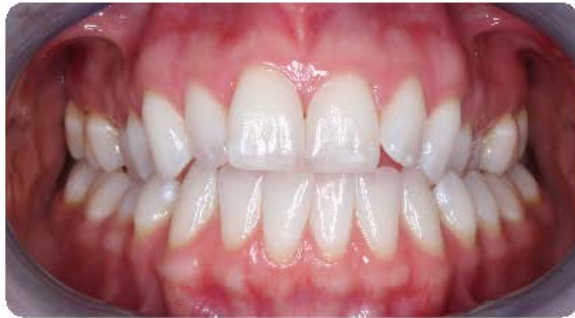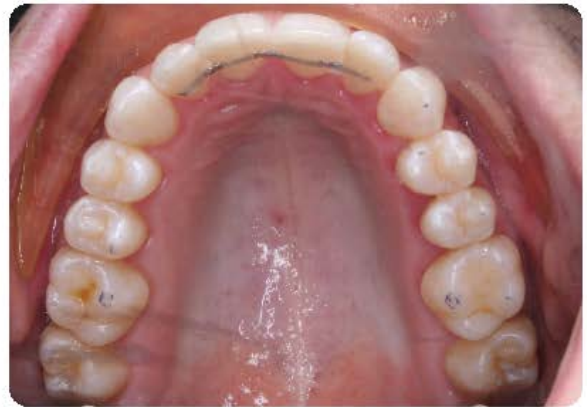Treated by Dr. Bella Shen Garnett

Initial



Final



30 year old Female
Crossbite, Narrow Arch forms, and Crowding treated with Invisalign®
Treatment Length: 10 months



Treated by Dr. Bella Shen Garnett